




# Drug-Coated Balloon Treatment in Symptomatic Intracranial High Grade Stenosis

## A Retrospective Study of 33 Patients

Luca Remonda<sup>1,2</sup> · Michael Diepers<sup>1</sup> · Jatta Berberat<sup>1</sup> · Timo Kahles<sup>3</sup> · Javier Anon<sup>1</sup> · Krassen Nedeltchev<sup>2,3</sup> · Philipp Gruber<sup>1</sup> 

Received: 19 February 2020 / Accepted: 30 June 2020 / Published online: 20 July 2020  
© Springer-Verlag GmbH Germany, part of Springer Nature 2020

### Abstract

**Purpose** Endovascular therapy (EVT) represents an alternative treatment modality for symptomatic intracranial high-grade atherosclerotic stenosis (sICAS); however, periprocedural complication rates as well as midterm restenosis rates represent relevant limitations of EVT. Drug-coated balloon percutaneous transluminal angioplasty (DCB-PTA) may overcome some of these shortcomings. The aim of this study was to assess feasibility and safety as well as the stroke recurrence rate in 33 patients.

**Methods** A retrospective, monocentric cohort study of sICAS patients treated with DCB-PTA. Outcome measures were the periprocedural intracranial complication rate, the recurrent stroke rate and mortality during follow-up.

**Results** This cohort study included 33 patients with 35 sICAS treated with DCB-PTA. The median age was 72 years (interquartile range, IQR 66–77 years); median clinical and mean radiological follow-up time was 9 months (IQR 3–22 months). Median preprocedural degree of stenosis (WASID) was 80% (IQR 73–80%) and median postprocedural residual stenosis degree (WASID) was 50% (IQR 33–60%). Intracranial periprocedural complications occurred in 2 (6%) patients. The overall restenosis rate was 15% ( $n=5$ ). In four patients a symptomatic ischemic re-event occurred within 7 months after the initial treatment. None of the patients died.

**Conclusion** This DCB-PTA cohort study showed a relatively low intracranial complication rate of 6% with a symptomatic recurrence rate of 12%. Larger trials are needed to validate these promising observations.

**Keywords** Drug-coated balloon (DCB) · Percutaneous transluminal angioplasty (PTA) · Intracranial atherosclerotic disease (ICAD) · Ischemic stroke · Intracranial stenosis

## Introduction

Intracranial atherosclerotic disease (ICAD) is a common cause of stroke worldwide with a high stroke recurrence rate despite best medical treatment [1, 2]. Endovascular treatment (EVT) of ICAD is associated with a high resteno-

sis rate (up to 30%) for both percutaneous transluminal angioplasty with stenting (PTAS) and percutaneous transluminal angioplasty (PTA) [3, 4], which is a major mid-term to long-term limitation of this treatment modality. To overcome this shortcoming, drug-eluting stents (DES) and drug-eluting balloons (DCB) have been developed, which have been successfully used to treat atherosclerotic heart disease in interventional cardiology [5].

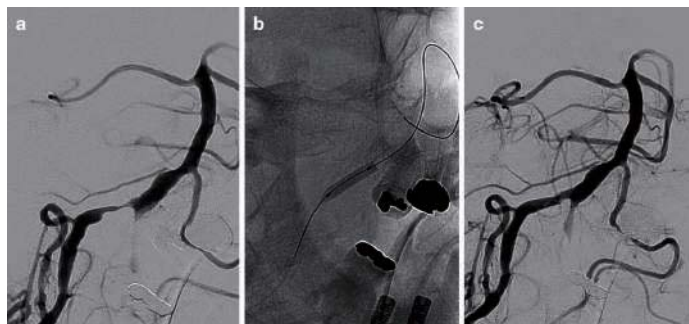
The drug-coated balloons (DCB) are mostly semicompliant balloons coated with an antiproliferative drug and a complex excipient enabling a rapid delivery of the active drug upon inflation to the vessel wall [6, 7]. These antiproliferative drugs inhibit smooth muscle cell prolifer-

✉ Philipp Gruber  
[philipp.gruber@ksa.ch](mailto:philipp.gruber@ksa.ch)

<sup>1</sup> Department of Neuroradiology, Kantonsspital Aarau, Tellstrasse 25, 5001 Aarau, Switzerland

<sup>2</sup> University Berne, Berne, Switzerland

<sup>3</sup> Department of Neurology, Kantonsspital Aarau, Aarau, Switzerland



**Fig. 1** Illustrative case. A 71-year-old patient with transient ischemic attacks (TIA) with dysarthria and dizziness due to a high-grade stenosis of the right intracranial vertebral artery. In his medical history, he already suffered from a cerebellar stroke and was under antiplatelet treatment and lipid-lowering treatment. **a** Preprocedural angiogram of this symptomatic, high-grade (Warfarin Aspirin in Symptomatic Intracranial Disease [WASID] trial stenosis grading criteria >95%), distal V4 segment vertebral artery stenosis of the right side. **b** The target lesion was treated with a single run paclitaxel drug-coated balloon (DCB) (2.0mm×10mm Sequent Please NEO; b.braun, Melsungen, Germany) PTA without predilatation using submaximal angioplasty technique. **c** Postprocedural angiogram of this symptomatic V4-segment vertebral artery stenosis with a residual stenosis (WASID <40%)

ation, which occurs after the PTA causes microinjuries due to natural immune inflammatory response [8].

In recent years, first cohort studies have shown feasibility and safety of DCB in symptomatic intracranial high-grade atherosclerotic stenosis (sICAS) ([9–11]; Fig. 1); however, the experience with DCB is limited since data are based on small patient numbers and short follow-up periods.

The aim of this study was to assess the feasibility and safety of DCB PTA in 33 patients.

## Methods

### Patient Selection

This retrospective monocenter cohort study at a tertiary stroke center was approved by the local ethics committee (EKNZ 2018-01204) with waived informed consent for the data analysis. Prior to the intervention, patients gave their informed consent to the DCB-PTA. Patients (≥18 years) with symptomatic, intracranial high-grade stenosis (WASID ≥70%) and electively (≥1 day after index event) treated with DCB-PTA between 2014 and 2019 were included in this retrospective data analysis. Patients with hyperacute (0–24 h) stroke or additional extracranial tandem stenosis, as well as patients with asymptomatic stenosis and without follow-up were excluded.

### Study Devices

In this study two different Paclitaxel coated DCB-PTA systems, either the Neuro Elutax SV (Aachen Resonance

GmbH, Aachen, Germany) or the SeQuent Please NEO (B Braun medical, Melsungen, Germany), were used [12, 13]. The Neuro Elutax SV represents the first CE certified DCB-PTA system specifically designed for neurovascular use. The SeQuent Please NEO is one of the latest cardiovascular DCB-PTA systems. The use of this DCB PTA system represents an off-label use. The decision on the type of DCB was at the discretion of the treating interventionalist.

### Procedure

All procedures were performed with the patient under general anesthesia. Prior to the intervention, all patients were either under dual antiplatelet therapy (DATP) with aspirin and clopidogrel or under an oral anticoagulant (OAC) combined with an antiplatelet monotherapy ( $n=3$ , 9%). An additional heparin bolus was administered, adjusted for body weight according to the activated coagulation time (ACT) blood test. In almost all cases a retrograde approach of the right common femoral artery was performed. A retrograde distal brachial artery access was obtained in only one patient. All interventions were performed on a biplane angiography system (Allura Xper, Philips, Amsterdam, The Netherlands). For the exact sizing of the DCB, the precise length and diameter of the stenosis was assessed by a 3D DSA prior to the PTA procedure. Under fluoroscopic guidance, the lesions were first explored by a microwire (synchro, Stryker Neurovascular, Kalamazoo, MI, USA), followed by the delivery of the DCB-PTA system in mono-rail technique. After careful positioning of the DCB over the lesion, the DCB was inflated for 30–60 s and a sub-maximal angioplasty maneuver was performed as described

elsewhere [14, 15]. If necessary, repeated angioplasty was done. No predilatation with a conventional angioplasty balloon or an additional stent deployment was performed.

Postprocedurally, the systolic blood pressure was kept at  $\leq 140$ –160 mm Hg. Thus, patients were monitored on a neurological intermediate care unit or intensive care unit (ICU) for 24 h. Most of the patients were kept on DAPT or OAC combined with a mono-antiplatelet therapy for 3 months. In 9 patients an immediate change to a monotherapy (aspirin [ASS] or clopidogrel alone) was done. In one case DAPT was reduced to ASS because of SAH. All patients were under a lipid lowering therapy and underwent medical modification of the cerebrovascular risk factors.

## Imaging

Cerebral angiography was used for the exact assessment of the preprocedural and post-procedural degree of intracranial stenosis according to the WASID criteria. Within 24 h postprocedural, all patients underwent an ultrasound (US) monitoring restenosis assessment. This US served also as a follow-up examination baseline. On each clinical follow-up, patients underwent an ultrasound control.

## Outcome Measures

Primary outcome parameters for safety and efficacy were the periprocedural symptomatic stroke rate (day 0–30), the stroke recurrence rate in the respective vascular territory and residual stenosis patency at follow-up assessed by a trained vascular neurologist. Restenosis was defined as a change in the US finding at follow-up that led from no stenosis or  $\leq 50\%$  stenosis to a  $>50\%$  stenosis degree with/without clinical symptoms in the respective vascular territory during the follow-up period.

Furthermore, we looked at periprocedural complication rate, mortality rate and favorable clinical outcome, defined as modified Ranking scale score  $\leq 2$  within 90 days.

## Results

This cohort comprised 33 treated patients with 35 lesions (Table 1). Median clinical and radiological follow-up was 9 months (interquartile range, IQR 3–22 months, range 1–56 months). In half of the patients ( $n=16$ ) a follow-up of more than 12 months was available. Median age was 72 years (IQR 66–77 years). Most of the patients were men. Hypertension and dyslipidemia were the most common vascular risk factors. Median NIHSS on admission was 1 (IQR 0–2). Median time from index event to intervention was 12 days (IQR 5–16 days). Most treated lesions were located in the posterior circulation. In two patients, se-

**Table 1** Population, stenosis and technical characteristics

| Population Characteristics                                      | N=33       |
|---|------------|
| Age in years, median (IQR)                                      | 72 (66–77) |
| Sex male, no. (%)   | 27 (82%)   |
| Hypertension, no. (%)   | 28 (85%)   |
| Dyslipidemia, no. (%)   | 27 (82%)   |
| Diabetes mellitus type II, no. (%)                              | 10 (30%)   |
| Obesity, no. (%)  | 17 (52%)   |
| Atrial fibrillation, no. (%)                                    | 3 (9%)     |
| Smoker, no. (%)   | 10 (30%)   |
| Previous stroke, no. (%)  | 9 (27%)    |
| NIHSS score on admission, median (IQR)                          | 1 (0–2)    |
| Time from index event to intervention in days, median (IQR)     | 12 (5–16)  |
| Follow-up period in months, median (IQR)                        | 9 (3–22)   |
| <i>Intracranial stenosis characteristics</i>                    |            |
| Left side, no. (%)  | 11 (16%)   |
| Preprocedural stenosis degree in percentage WASID, median (IQR) | 80 (73–80) |
| Intradural vertebral artery, no. (%)                            | 10 (30%)   |
| Basilar artery, no. (%)   | 10 (30%)   |
| Distal intracranial carotid artery, no. (%)                     | 9 (27%)    |
| Middle cerebral artery, no. (%)                                 | 6 (18%)    |
| <i>Technical characteristics</i>                                |            |
| General anesthesia, no. (%)                                     | 33 (100%)  |
| Neuro Elutax SV (Aachen Resonance, Aachen, Germany)             | 7 (21%)    |
| Sequent Please NEO (bbraun, Melsungen, Germany)                 | 26 (79%)   |

IQR interquartile range, NIHSS National Institute of Health Stroke Scale, no number, WASID warfarin aspirin in symptomatic intracranial disease

rial lesions of the vertebral and basilar artery were treated. Median preinterventional degree of stenosis (WASID) was 80% (IQR 73–80%). The most commonly used DCB-PTA system was the SeQuent Please NEO PTA system.

Mean postprocedural stenosis degree (WASID) was 50% (IQR 33–60%) (Table 2).

A minor ischemic event with bilateral ischemic lesions occurred within 24 h after the intervention in only one patient. In one patient, a dissection of the intradural vertebral artery with consecutive subarachnoid hemorrhage occurred during the interventional maneuver. Fortunately, the patient recovered completely from this incident. Furthermore, a hemodynamic relevant groin hematoma at the puncture side occurred that needed vascular surgery but there was no vasospasm, vessel perforation or in-hospital or out-of-hospital deaths during the follow-up reported. The 24 h postprocedural US and the follow-up US results remained stable with no evidence of stenosis in 37% and 42% of the cases,  $\leq 50\%$  stenosis in 42% and 40% and  $>50\%$  stenosis in 21% and 18%, respectively. On follow-up, the overall restenosis rate was 15% ( $n=5$ ). Of these 5 patients with

**Table 2** Summary of outcome measures

| Outcome measures   | N=33       |
|--|------------|
| Modified Ranking Scale (mRS) score at follow-up, median (IQR)      | 1 (0–1)    |
| Postprocedural stenosis degree in percentage (WASID), median (IQR) | 50 (33–60) |
| Overall restenosis rate, no. (%) <sup>a</sup>                      | 5 (15%)    |
| Symptomatic ischemic re-events, no. (%)                            | 4 (12%)    |
| Relevant asymptomatic restenosis rate, no. (%)                     | 1 (3%)     |
| Intracranial periprocedural complications, no. (%)                 | 2 (6%)     |
| Extracranial periprocedural complications, no. (%)                 | 1 (3%)     |
| Death rate within the follow-up period, no. (%)                    | 0 (0%)     |

IQR interquartile range, *NHSS* National Institute of Health Stroke Scale, *mRS* modified Ranking Scale Score, *no* number, *WASID* warfarin aspirin in symptomatic intracranial disease

<sup>a</sup>This overall restenosis rate consists of the relevant asymptomatic re-stenosis rate as well the restenoses with symptomatic ischemic re-events

restenosis symptomatic ischemic re-events occurred in 4 (12%) with a median intervention to re-event interval of 7 months (IQR 7–9.5 months). Median degree of restenosis (WASID) of these 4 symptomatic patients, who received conventional cerebral angiography when presenting with new symptoms, was 80% (IQR 78–83%). All of these 4 patients had a postprocedural degree of stenosis (WASID) of  $\geq 50\%$  after DCB-PTA for the index event. In addition, all of them had a history of smoking and 2 out of 4 patients suffered from diabetes mellitus. In addition, in one case a severe asymptomatic restenosis occurred after 6 months without clinical symptoms. Finally, 4 of these patients were successfully retreated with DCB-PTA.

## Discussion

This retrospective cohort study demonstrated the feasibility and safety of DCB-PTA treatment with a low intracranial periprocedural complication rate of 6% and a symptomatic recurrence rate of 12%.

Only limited data on DCB-PTA in sICAD patients are available [9–11]. Treatment of sICAD patients with high-grade stenosis ( $\geq 70$ –99%) remains challenging as the only approved treatment regimen (best medical treatment) revealed a disappointingly high stroke recurrence rate with 21% within 1.8 years [16]. Endovascular treatment in these patients is limited due to the high periprocedural complication rate as well as the high restenosis rate in the follow-up period; however, the high periprocedural complication rates [17] have recently been challenged by the results of the WAVE trial (2.6%) [18]. In addition, data from a few DCB-PTA cohort studies revealed comparatively low periprocedural complication rates ranging from 0% to 6.5% that are supported by our findings with an intracranial com-

plication rate of 6% [9–11]. The reason for the lower complication rates may be due to the advances of material technology enabling a better maneuverability and navigability, the growing experience of the treatment of intracranial lesions since the era of endovascular stroke treatment and careful patient selection [19].

A known long-term complication is restenosis secondary to neointimal hyperplasia induced by mechanical microinjuries during dilatation or stent deployment [20]. Under the assumption that a restenosis with  $\geq 50\%$  luminal loss may provoke cerebral ischemic events again [21], the prevention of such lesions is of utmost importance. Despite promising results [22], DES have never become a standard procedure in the neurovascular field. The PTA alone revealed a similar periprocedural complication rate compared to PTAS but seems to have better long-term results regarding re-events compared to PTAS [23]; however, large RCT are lacking. Nevertheless, these results might also indicate an advantage in the long-term efficacy for DCB-PTA. Recent data from DCB PTA studies have shown convincing results in the treatment of sICAD patients [9–11]. Our findings support these results. Within a median follow-up of 9 months (IQR 3–22 months), 12% symptomatic re-events occurred, which is lower than the natural course with 21%, as reported in cohorts of sICAS patients treated with best medical treatment (BMT) only [16]. The recurrence of ischemic symptoms usually occurred around 7 months after the intervention, which has also been described for patients treated with PTAS [21]. All of these patients were smokers and half of them also suffered from diabetes, while the original cohort consisted of only 30% smokers and 30% diabetes patients. This observation is not surprising, as diabetic patients in particular tend to develop restenosis after cardiological PTA [24]. Interestingly, the pathophysiological influence of smoking on the development of restenosis after percutaneous coronary intervention has not yet been defined [25]. Nevertheless, our data suggest that these two vascular risk factors may promote stenosis in cerebral vessels. Furthermore, due to our submaximal angioplasty technique, the initial median residual stenosis of 50% may be too high in these cases. Probably, the residual stenosis should be lower in these cases.

Limitations are the retrospective nature of this cohort and the relatively small number of patients due to the fact that DCP-PTA is still an off-label use in the neurovascular setting. Additionally, the radiological follow-up control with US only enables an approximate assessment of the treated stenosis; however, US follow-up is only justified because it is non-invasive and does not expose patients to additional radiation or possible complications of endovascular surgery. Furthermore, it is cost-effective.



## Conclusion

Drug-coated balloon (DCB) angioplasty in symptomatic intracranial high-grade stenosis shows a relatively low intracranial complication rate of 6% with a symptomatic recurrence rate of 12%. Larger trials are needed to further validate these promising observations.

**Funding** This research received no specific grant from any funding agency of the public, commercial, or not-for-profit sectors.

**Author Contribution** LR was responsible for the conception and design of the work, revising it critically for important intellectual content and final approval of the version to be published. MD, JB made substantial contributions to the conception and design of the work and revising it critically for important intellectual content. TK, JA, KN revising it critically for important intellectual content. PG was responsible for the conception and design of the work as well as acquisition, analysis, and interpretation of data and writing the manuscript.

## Compliance with ethical guidelines

**Conflict of interest** L. Remonda, M. Diepers, J. Berberat, T. Kahles, J. Anon, K. Nedeltchev and P. Gruber declare that they have no competing interests.


**Ethical standards** The ethical approval was given by the local ethics committee (EKNZ 2018-01204). There was a waived informed consent modus for this study

## References

- Wang Y, Meng R, Liu G, Cao C, Chen F, Jin K, Ji X, Cao G. Intracranial atherosclerotic disease. *Neurobiol Dis*. 2019;124:118–32.
- Vellimana AK, Ford AL, Lee JM, Derdeyn CP, Zipfel GJ. Symptomatic intracranial arterial disease: incidence, natural history, diagnosis, and management. *Neurosurg Focus*. 2011;30:E14.
- Wolfe TJ, Fitzsimmons BF, Hussain SI, Lynch JR, Zaidat OO. Long term clinical and angiographic outcomes with the Wingspan stent for treatment of symptomatic 50–99% intracranial atherosclerosis: single center experience in 51 cases. *J Neurointerv Surg*. 2009;1:40–3.
- Wojak JC, Dunlap DC, Hargrave KR, DeAlvarez LA, Culbertson HS, Connors JJ 3rd. Intracranial angioplasty and stenting: long-term results from a single center. *AJNR Am J Neuroradiol*. 2006;27:1882–92.
- Jackson D, Tong D, Layland J. A review of the coronary applications of the drug coated balloon. *Int J Cardiol*. 2017;226:77–86.
- Mohiaddin H, Wong TDFK, Burke-Gaffney A, Bogle RG. Drug-coated balloon-only percutaneous coronary intervention for the treatment of de novo coronary artery disease: a systematic review. *Cardiol Ther*. 2018;7:127–49.
- Speck U, Stolzberg N, Peters D, Scheller B. How does a drug-coated balloon work? Overview of coating techniques and their impact. *J Cardiovasc Surg (Torino)*. 2016;57:3–11.
- Tesfamariam B. Local arterial wall drug delivery using balloon catheter system. *J Control Release*. 2016;238:149–56.
- Gruber P, Garcia-Esperon C, Berberat J, Kahles T, Hlavica M, Anon J, Diepers M, Nedeltchev K, Remonda L. Neuro Elutax SV drug-eluting balloon versus Wingspan stent system in symptomatic intracranial high-grade stenosis: a single-center experience. *J Neurointerv Surg*. 2018;10:e32.
- Gruber P, Braun C, Kahles T, Hlavica M, Anon J, Diepers M, Nedeltchev K, Berberat J, Remonda L. Percutaneous transluminal angioplasty using the novel drug-coated balloon catheter SeQuent Please NEO for the treatment of symptomatic intracranial severe stenosis: feasibility and safety study. *J Neurointerv Surg*. 2019;11:719–22.
- Han J, Zhang J, Zhang X, Zhang J, Song Y, Zhao W, Zheng M, Sun L, Wang W. Drug-coated balloons for the treatment of symptomatic intracranial atherosclerosis: initial experience and follow-up outcome. *J Neurointerv Surg*. 2019;11:569–73.
- B. Braun. Sequent Please NEO. 2019. <https://www.bbraun.com/en/products/b2/sequent-please-neo.html>. Accessed 22 Sept 2019.
- Aachen Resonance. Neuro Elutax. 2019. [http://www.lamedical.org/wp-content/uploads/2014/04/Elutax\\_SV\\_NEURO\\_Broschüre](http://www.lamedical.org/wp-content/uploads/2014/04/Elutax_SV_NEURO_Broschüre). Accessed 22 Sept 2019.
- Dumont TM, Sonig A, Mokin M, Eller JL, Sorkin GC, Snyder KV, Hopkins LN, Levy EI, Siddiqui AH. Submaximal angioplasty for symptomatic intracranial atherosclerosis: a prospective Phase I study. *J Neurosurg*. 2016;125:964–71.
- Connors JJ 3rd, Wojak JC. Percutaneous transluminal angioplasty for intracranial atherosclerotic lesions: evolution of technique and short-term results. *J Neurosurg*. 1999;91:415–23.
- Chimowitz MI, Lynn MJ, Howlett-Smith H, Stern BJ, Hertzberg VS, Frankel MR, et al. Comparison of warfarin and aspirin for symptomatic intracranial arterial stenosis. *N Engl J Med*. 2005;352:1305–16.
- Chimowitz MI, Lynn MJ, Derdeyn CP, Turan TN, Fiorella D, Lane BF, et al. Stenting versus aggressive medical therapy for intracranial arterial stenosis. *N Engl J Med*. 2011;365:993–1003.
- Alexander MJ, Zauner A, Chaloupka JC, Baxter B, Callison RC, Gupta R, et al. WEAVE Trial: Final Results in 152 On-Label Patients. *Stroke*. 2019;50:889–94.
- Gruber P, Remonda L. Device profile of different paclitaxel-coated balloons: Neuro Elutax SV, Elutax ‘3’ Neuro and SeQuent Please NEO for the treatment of symptomatic intracranial high-grade stenosis: overview of their feasibility and safety. *Expert Rev Med Devices*. 2020;17:87–92.
- Papafakis MI, Chatzizisis YS, Naka KK, Giannoglou GD, Michalis LK. Drug-eluting stent restenosis: effect of drug type, release kinetics, hemodynamics and coating strategy. *Pharmacol Ther*. 2012;134:43–53.
- Vajda Z, Gütte T, Perez MA, Heuschmid A, Schmid E, Bänzner H, Henkes H. Neurovascular in-stent stenoses: treatment with conventional and drug-eluting balloons. *AJNR Am J Neuroradiol*. 2011;32:1942–7.
- Vajda Z, Aguilar M, Göhringer T, Horvath-Rizea D, Bänzner H, Henkes H. Treatment of intracranial atherosclerotic disease with a balloon-expandable paclitaxel eluting stent: procedural safety, efficacy and mid-term patency. *Clin Neuroradiol*. 2012;22:227–33.
- Kadooka K, Hagenbuch N, Anagnostakou V, Valavanis A, Kulcsár Z. Safety and efficacy of balloon angioplasty in symptomatic intracranial stenosis: A systematic review and meta-analysis. *J Neuroradiol*. 2020;47:27–32.
- Buccheri D, Piraino D, Andolina G, Cortese B. Understanding and managing in-stent restenosis: a review of clinical data, from pathogenesis to treatment. *J Thorac Dis*. 2016;8:E1150–62.
- Cohen DJ, Doucet M, Cutlip DE, Ho KK, Popma JJ, Kuntz RE. Impact of smoking on clinical and angiographic restenosis after percutaneous coronary intervention: another smoker's paradox? *Circulation*. 2001;104:773–8.

# Transcranial duplex ultrasound monitoring of intracranial arterial stenosis treated with ELUTAX “3” drug-eluting balloon

Elena Elvira Soler , Blanca Serrano Serrano, Nicolás López Hernández, Natasha Guevara Dalrymple, Sarai Moliner Castellano and Jose Ignacio Gallego León

Interventional Neuroradiology  
1–5  
© The Author(s) 2020  
Article reuse guidelines:  
sagepub.com/journals-permissions  
DOI: 10.1177/1591019920929812  
journals.sagepub.com/home/ine  


## Abstract

We report the results of transcranial ultrasound monitoring in three patients with intracranial arterial stenosis of the middle cerebral artery treated with the only drug-eluting balloon certificated for intracranial use in highly symptomatic intracranial arterial stenosis, ELUTAX “3” (AR Baltic Medical). We performed transcranial Doppler ultrasounds 24 h, 72 h, 10 days, 15 days and 30 days after the angioplasty, thereby measuring mean flow velocity (MFV) in the maximum stenosis area in patients with symptomatic steno-occlusive disease of the middle cerebral artery treated with ELUTAX “3”. Two patients were treated during mechanical thrombectomy (MT) due to acute ischemic stroke and one patient was treated on elective basis due to symptomatic pre-occlusive stenosis, with recurrent transient ischemic attacks (TIAs) refractory to medical therapy. In Case 1, the first transcranial Doppler ultrasounds evidenced MFV of 348 cm/s, with progressive MFV reduction until 15 days post-treatment, with MFV of 177 cm/s. In Case 2, 24 h after angioplasty had an MFV of 258 cm/s, decreasing to 103 cm/s at 30 days. Case 3 had an MFV of 436 cm/s before angioplasty that immediately decreased after the procedure to 364 cm/s, with a final MFV of 260 cm/s at 30 days. We have recorded a progressive MFV reduction in intracranial arterial stenosis, with better outcomes in patients treated during MT. In our experience, the use of ELUTAX “3” for the treatment of symptomatic intracranial arterial stenosis achieves a progressive improvement of stenosis, evident in the first weeks, to a higher extent in cases of occlusive thrombosis. More studies are needed to provide more information about this device.

## Keywords

Intracranial stenosis, angioplasty, drug-eluting balloon, ELUTAX “3”

Received 5 March 2020; accepted 30 April 2020

## Introduction

The first-line treatment for intracranial arterial stenosis (ICS) is currently medical therapy, as clinical trials such as SAMMPRIS show that percutaneous transluminal angioplasty and stenting involves a high percentage of periprocedural complications (14.7%) and up to 34% recurrences, most of them due to restenosis.<sup>1</sup>

A drug-eluting balloon (DEB) has been recently developed specifically for intracranial use, consisting of paclitaxel (ELUTAX “3”), a potent lipophilic anticancer agent with antiproliferative action on endovascular smooth muscle cells, that reduces intimal hyperplasia and, therefore, restenosis.<sup>2</sup> It is the only DEB with CE mark (*Conformité Européenne*, CE) for intracranial use in highly symptomatic ICS,<sup>3</sup> but to date there are no follow-up studies available that describe the hemodynamic changes occurring in ICS following treatment with intraarterial paclitaxel.

A simple, useful tool to monitor hemodynamic changes in intracranial arterial flow is transcranial

Doppler ultrasounds (TCD).<sup>4</sup> This non-invasive technique can be used to measure mean flow velocity (MFV) in the area of maximum stenosis and, therefore, correlate it with the ICS degree.<sup>5,6</sup>

We report the results of ultrasound monitoring in three patients with intracranial stenosis of the middle cerebral artery (MCA) treated at our site with ELUTAX “3” (AR Baltic Medical).

## Methods

Patients with symptomatic steno-occlusive disease of the MCA treated in our site with ELUTAX “3” were screened.

Department of Neurology, Alicante General University Hospital, Alicante, Spain

### Corresponding author:

Elena Elvira Soler, Department of Neurology, Alicante General University Hospital, C/Pintor Baeza, n 11., Alicante 03010, Spain.  
Email: elenaelvirasoler@gmail.com

In all cases, the target lesion was crossed using a Traxcess 0.014" microwire (MicroVention, Tustin, California, USA) and a microcatheter was advanced distal to the lesion to perform an initial. We used Trevo Pro 18 (Stryker Neurovascular, Kalamazoo, MI, USA) as it is part of the standard equipment for the treatment of the stroke in our hospital. With the tip of the guidewire in a distal branch of the target artery, ELUTAX "3" was then advanced with mono-rail technique over an exchange system by adding a docking wire.

The size and length of the balloon was chosen based on the characteristics of the lesion.

We performed control ultrasound studies 24 h, 72 h, 10 days, 15 days and 30 days after angioplasty, thereby measuring MFV in the maximum stenosis area.

The studies were performed at the neurosonology laboratory of a tertiary hospital by transcranial color-coded ultrasonography, under baseline conditions, through the temporal window with probe at 1–4 MHz (Philips CX50), with the patient lying on his back, at rest and with normal blood pressure values. In case of insufficient temporal acoustic window, it was allowed to use the echo-enhancer, which was used in the rest of the tests in this patient.

## Results

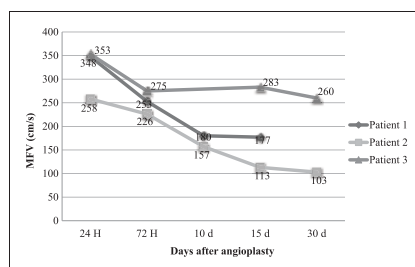
Two patients were treated with ELUTAX "3" during mechanical thrombectomy (MT) due to acute ischemic stroke, in the first case for impossibility to perform it with the previous thrombus aspiration device,

with suspected arterial occlusion due to intracranial atherosclerosis, and in the second case due to progressive stenosis after thrombus aspiration.

Patient 3 was treated on an elective basis due to symptomatic pre-occlusive stenosis of the left MCA, with recurrent TIAs, refractory to aggressive medical therapy.

Table 1 shows the demographic and clinical characteristics of the patients treated with ELUTAX "3".

*Patient 1* is a 70-year old man with a history of left carotid stroke six months before in his country of origin treated with primary MT, with residual modified Rankin Scale of 1 due to intracranial atheromatosis. He suffered a new stroke of the left MCA (occlusion of M1 segment) treated with primary TM due to the uncertain onset. During the procedure, moderate to severe focal residual stenosis was



**Figure 1.** Hemodynamic changes after ELUTAX "3" in ICS measured with TCD. MFV: mean flow velocity.

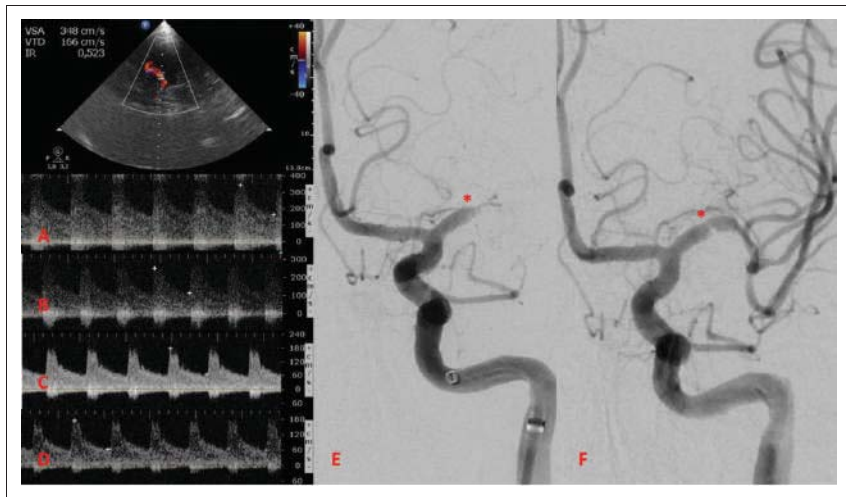
**Table 1.** Demographic and clinical characteristics of the patients treated with ELUTAX "3".

|  | Patient 1   | Patient 2                              | Patient 3                                      |
|--|---|--|--|
| Age (years)  | 70  | 66                                     | 41   |
| Sex  | Male  | Male                                   | Male   |
| Vascular risk factors  | HT, DLP   | HT, DLP, active smoker (40 years-pack) | HT, obesity, OSAS                              |
| Treatment on admission                                       | Clopidogrel 75 mg, Carbasalate calcium 100 mg, Atorvastatin 40 mg                   | Pravastatin 40 mg                      | Acetyl salicylic acid 150 mg                   |
| Clinical signs   | Ischemic stroke left MCA  | Ischemic stroke right MCA              | Recurrent TIAs                                 |
| History of stroke/previous TIA                               | Yes   | No                                     | Yes  |
| National Institute Health Stroke Scale on admission (points) | 15  | 18                                     | 0  |
| ICS site   | Left proximal MCA   | Right proximal MCA                     | Left proximal MCA                              |
| Treatment with ELUTAX "3"                                    | During MT   | During MT                              | Deferred. TIAs refractory to medical treatment |
| ICS degree in DSA after immediate treatment                  | DSA: ICS 50–69%   | DSA: ICS 50–69%                        | DSA: ICS >90%                                  |
| Antithrombotic treatment post-ELUTAX "3"                     | – 3 months clopidogrel 75 mg + acetyl salicylic acid 100 mg<br>– Atorvastatin 80 mg |  |  |
| One month modified Rankin Scale                              | 3   | 1                                      | 0  |

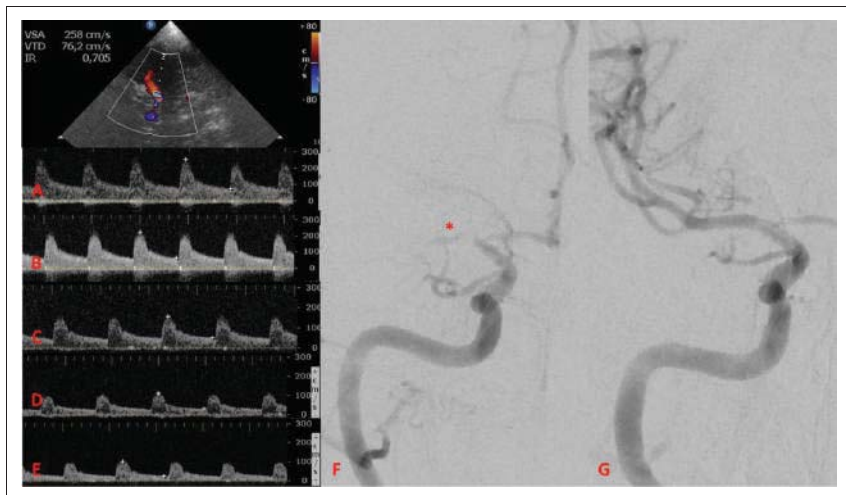
MCA: middle cerebral artery; ICS: intracranial arterial stenosis; MT: mechanical thrombectomy; HT: hypertension; DLP: dyslipidemia; OSAS: obstructive sleep apnoea syndrome; TIA: transient ischemic attack; DSA: digital subtraction angiography.

evidenced in the proximal segment of M1 of the left MCA with a trend to reocclusion and difficulty to advance the guide, for which angioplasty was performed with ELUTAX “3”, achieving complete revascularization with modified Thrombolysis in Cerebral Infarction (mTICI) 3.

The first TCD control performed at 24 h evidenced MFV of 348 cm/s, with progressive MFV reduction until the last TCD performed at 15 days post-treatment, with MFV of 177 cm/s. No subsequent ultrasonographic controls are available as he returned to his country (see Figures 1 and 2).



**Figure 2.** TCD control in Patient 1 at 24 h after angioplasty with ELUTAX “3” (a), 72 h (b), 10 days (c) and 15 days (d) after treatment. (e) and (f) correspond to DSA studies during MT: (e) shows left M1 occlusion (\*) and (f) shows the residual stenosis (\*) after angioplasty with the DEB.



**Figure 3.** TCD control in Patient 2 at 24 h after angioplasty with ELUTAX “3” (a), 72 h (b), 10 days (c), 15 days (d) and 30 days (e) after treatment. (f) and (g) correspond to DSA studies during MT: (f) shows right proximal M1 occlusion (\*) and (g) shows the recanalization after angioplasty with the DEB.

*Patient 2* is a 66-year old man with ischemic stroke of the right MCA due to atheromatous occlusion of the M1 segment, treated with fibrinolysis iv and rescue TM, initially achieving partial revascularization with high-grade residual stenosis, performing angioplasty with ELUTAX “3” and achieving complete revascularization (mTICI 3).

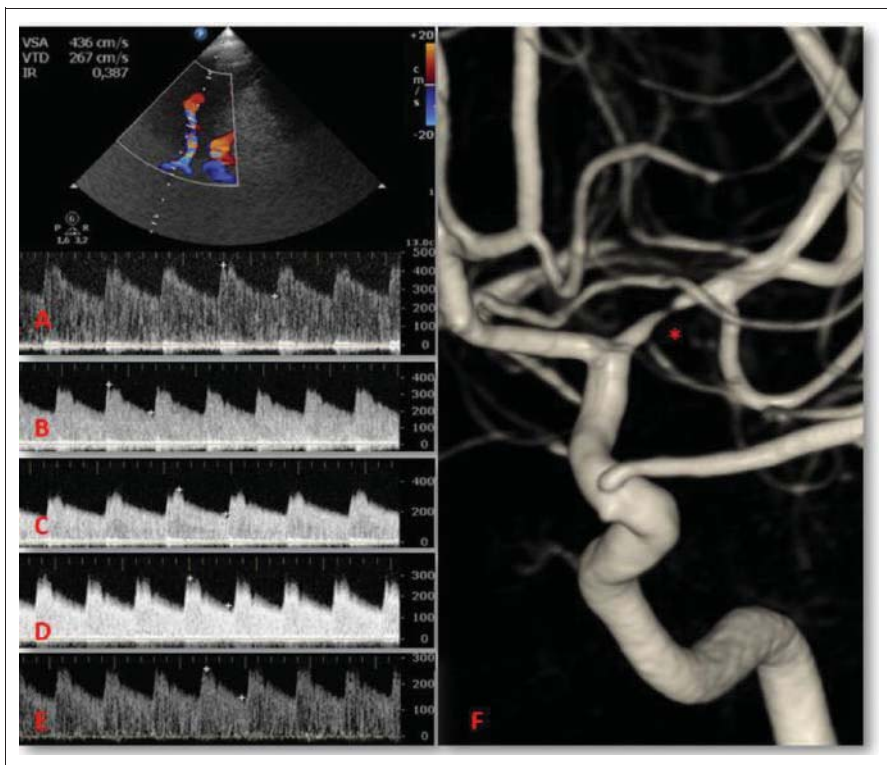
Initially at 24 h after ELUTAX “3”, he had MFV measured with TCD of 258 cm/s, decreasing to 103 cm/s at 30 days (see Figures 1 and 3). The patient had a progressive clinical improvement, with National Institute Health Stroke Scale 2 points at 30 days.

*Patient 3* is a 41-year old man with finding of pre-occlusive stenosis in proximal segment of the left MCA after study of recurrent left carotid TIAs. The patient had two to three TIAs daily despite the accurate hemodynamic control and the aggressive medical therapy with dual antiplatelet treatment and high-dose statin. The last two TIAs occurred a few hours before angioplasty with ELUTAX “3”, and he has been asymptomatic since then.

Before the treatment, a neurosonologic study was performed, finding in the left MCA an area of narrowing of the flow with aliasing and murmur and MFV of 436 cm/s, consistent with severe stenosis at this level (which required administration of echo-enhancer due to the absence of transtemporal window in all the tests). Immediately after the angioplasty (1 h post-treatment), a MFV reduction to 364 cm/s was shown. In the next controls, a progressive reduction was identified in the MFV, with final MFV of 260 cm/s at 30 days (see Figures 1 and 4). There were no immediate complications in any patient after the procedure. No patient had more ischemic events in the first months after the procedure.

## Discussion

ELUTAX “3” is the only CE-marked DEB for the treatment of ICS and its use is indicated in symptomatic, high-grade ICS. Several studies have shown that the restenosis rate is lower with ELUTAX “3” than



**Figure 4.** TCD control in Patient 3 before angioplasty with ELUTAX “3” (a), 1 h (b), 24 h (c), 72 h (d) and 30 days (e) after treatment. (f) corresponds to 3D DSA study of the same patient, with critical left MCA stenosis (\*).

with conventional metal stents, but they are limited to case series or cohort studies with a small sample size.<sup>1–3,7–10</sup>

As far as we know, this is the first article that describes the time course of hemodynamic changes caused by ELUTAX “3” in the ICS, measured by TCD. We have used this DEB in two patients coming to our site with acute ischemic stroke of the MCA with severe residual ICS and in one patient with high-grade symptomatic drug-resistant stenosis of the MCA.

We have recorded a progressive MFV reduction of ICS, probably due to, on the one hand, the immediate mechanical effect of angioplasty over ICS (enlargement of ICS that we saw in one patient where we could perform TCD before the angioplasty and immediately after it) and, on the other hand, to the antiproliferative endovascular effect occurring over the long term, though it is already evident in the first weeks.

We have also seen better outcomes in the MFV reduction in patients treated during MT with ELUTAX “3” (Patients 1 and 2) than in the patient with chronic ICS (Patient 3). This can be due to the characteristics of the most chronic plaques, possibly with more calcification and more fibroblastic and/or cellular content, which would lead the MFV improvement to be evidenced later. In addition, the latter patient had a higher degree of ICS initially and therefore higher MFV, which can also affect the results.

We have no control TCD at 10 days due to the difficulty for Patient 3 to travel to our site.

In our experience, the use of ELUTAX “3” for the treatment of symptomatic ICS achieves a progressive improvement of stenosis, which becomes evident in the first weeks, to a higher extent in the case of occlusive thrombosis. Larger sample studies, with a longer follow-up time, are required to provide more information about this new device.


#### Declaration of conflicting interests

The author(s) declared no potential conflicts of interest with respect to the research, authorship, and/or publication of this article.

#### Funding

The author(s) received no financial support for the research, authorship, and/or publication of this article.


#### ORCID iD

Elena Elvira Soler  <https://orcid.org/0000-0002-7840-6022>

#### References

1. Chimowitz MI, Lynn MJ, Derdeyn CP, et al. Stenting versus aggressive medical therapy for intracranial arterial stenosis. *N Engl J Med* 2011; 365: 993–1003.
2. Vajda Z, Aguilar M, Göhringer T, et al. Treatment of intracranial atherosclerotic disease with a balloon-expandable paclitaxel eluting stent: procedural safety, efficacy and mid-term patency. *Clin Neuroradiol* 2012; 22: 227–233.
3. Gruber P, Garcia-Esperon C, Berberat J, et al. Neuro Elutax SV drug-eluting balloon versus Wingspan stent system in symptomatic intracranial high-grade stenosis: a single-center experience. *J NeuroIntervent Surg* 2018; 10: e32.
4. Valaikiene J, Ryliskyte L, Valaika A, et al. A High Prevalence of Intracranial Stenosis in Patients with Coronary Artery Disease and the Diagnostic Value of Transcranial Duplex Sonography. *J Stroke Cerebrovasc Dis* 2019; 28(4): 1015–1021.
5. Zhao L, Barlinn K, Sharma VK, et al. Velocity criteria for intracranial stenosis revisited: an international multicenter study of transcranial Doppler and digital subtraction angiography. *Stroke* 2011; 42: 3429–3434.
6. Chen L, Zhan Q, Ma C, et al. Reproducibility of middle cerebral artery stenosis measurements by DSA: comparison of the NASCET and WASID methods. Jung RE, editor. *PLoS One* 2015; 10: e0130991.
7. Ye G, Yin X, Yang X, et al. Efficacy and safety of drug-eluting stent for the intracranial atherosclerotic disease: a systematic review and meta-analysis. *J Clin Neurosci* 2019; 59: 112–118.
8. Kadooka K, Hagenbuch N, Anagnostakou V, et al. Safety and efficacy of balloon angioplasty in symptomatic intracranial stenosis: a systematic review and meta-analysis. *J Neuroradiol* 2020; 47: 27–32.
9. Yoon NK, Awad A-W, Kalani MYS, et al. Stent technology in ischemic stroke. *Neurosurg Focus* 2017; 42(4): E11.
10. Shin YS, Kim BM, Suh SH, et al. Wingspan stenting for intracranial atherosclerotic stenosis: clinical outcomes and risk factors for in-stent restenosis. *Neurosurgery* 2013; 72: 596–604.





## Technical notes &amp; surgical techniques

## Treatment of acute occlusion due to intracranial atherosclerosis by angioplasty with ELUTAX “3” drug-eluting balloon

Blanca Serrano Serrano<sup>a,\*</sup>, Francisco Hernández Fernández<sup>b</sup>, Nicolás López Hernández<sup>a</sup>, Elena Elvira Soler<sup>a</sup>, Giorgio Barbieri<sup>c</sup>, Juan D. Molina Nuevo<sup>d</sup>

<sup>a</sup> Neurology Department, Hospital General Universitario de Alicante, Spain

<sup>b</sup> Neurology Department, Complejo Hospitalario Universitario de Albacete, Spain

<sup>c</sup> Radiology Department, Hospital General Universitario de Alicante, Spain

<sup>d</sup> Radiology Department, Complejo Hospitalario Universitario de Albacete, Spain

## A B S T R A C T

**Background:** Intracranial atherosclerotic disease is an important cause of ischemic stroke due to large vessel occlusion. The acute management of these occlusions is challenging and associates an important risk of complications, especially when mechanical thrombectomy does not achieve vessel recanalization. In this context, the ELUTAX “3” drug-eluting balloon has been designed for neurological procedures. Nevertheless, there is not enough clinical evidence of this balloon. We report our experience with ELUTAX “3” during mechanical thrombectomy, explaining the technical details and the outcome of the procedure, the subsequent management and the clinical evolution of the patients.

**Methods:** We report four cases of patients with acute stroke due to intracranial atherosclerosis who were treated with the Elutax “3” drug-eluting-balloon.

**Results:** Using the Elutax “3” we achieved a complete recovery of the occluded arteries caliber (mTICI 3) and a good performance status of our patients on discharge, with the only remarkable complication of a mild asymptomatic subarachnoid bleeding in one of them. The 90-days mRS in those patients was less or equal than 2, and they have not experienced recurrence of the strokes in the long term follow-up.

**Conclusions:** In our experience, the Elutax “3” might be a safe and effective therapeutic option in acute large vessel occlusion secondary to intracranial atherosclerotic disease. However, further studies will be necessary to evaluate the efficacy and safety of this device.

## 1. Introduction

ICAD is a major cause of ischemic stroke due to LVO worldwide, especially in Asian countries, where it is more common than cardioembolic strokes [1–3].

The management of acute LVO secondary to ICAD is technically more challenging and associates greater risk of recurrence of the stroke. Although endovascular therapy has demonstrated to be superior to standard medical treatment in anterior circulation LVOs [4], in ICAD-related strokes MT often leads to re-occlusion, procedure complications and residual stenosis [5].

Following the results of the SAMMPRIS and VISSIT studies, aggressive medical treatment has been established as therapy of choice in chronic symptomatic ICAD [6,7]. However, acute management of ICAD-related strokes is controversial, especially when MT is not able to

recanalize the vessel. Different approaches, such as performing an angioplasty with or without placing a stent [8,9] or using glycoprotein IIb/IIIa inhibitors [10–12] have been proposed. Neither of them are exempt of complications, and their effectiveness is not well established. Hence, new treatment strategies have been searched for.

In this context, the ELUTAX “3” DEB (AR Baltic Medical) has been recently designed. It is a hydrophilic device created specifically for neurological procedures. This balloon has a 360° and 2.2 µg/mm<sup>2</sup> paclitaxel coating and, after placing it in the area of maximum stenosis, it is inflated with a maximum pressure of 6 ATM for at least 30 s, releasing the drug film. Paclitaxel then coats the surface of the stenosis for 12 additional weeks, preventing restenosis thanks to its cytostatic effect on the intimal vascular layer. This is a new therapeutic option with some interesting advantages: the patient does not need dual antiplatelet therapy, comparing to conventional stents, and the device has a local

**Abbreviations:** ACA, anterior cerebral artery; ASA, acetyl salicylic acid; ASPECTS, Alberta Stroke Program CT Score; ATM, atmosphere; BA, basilar artery; CT, Computed Tomography; DAPT, Dual anti-platelet therapy; DEB, Drug-eluting balloon; ICA, Internal Carotid Artery; ICAD, Intracranial atherosclerotic disease; ICH, intracranial hemorrhage; LVO, Large vessel occlusion; MCA, middle cerebral artery; mRS, modified Rankin Scale; MT, Mechanical thrombectomy; mTICI, modified Thrombolysis in Cerebral Infarction; NIHSS, National Institute Health Stroke Scale; TCD, transcranial Doppler

\* Corresponding author at: C/ Bailarín José Espadero, 12, escalera 5, 1C, 03015 Alicante, Spain.

E-mail address: [blanca.se92@gmail.com](mailto:blanca.se92@gmail.com) (B. Serrano Serrano).

<https://doi.org/10.1016/j.inat.2020.100768>

Received 24 March 2020; Received in revised form 6 May 2020; Accepted 9 May 2020

2214-7519/ © 2020 Published by Elsevier B.V. This is an open access article under the CC BY-NC-ND license (<http://creativecommons.org/licenses/by-nc-nd/4.0/>).

**Table 1**

Characteristics of the patients, arterial occlusions, outcome of the procedures, complications, clinical evolution and management.

|                       | Patient 1                              | Patient 2                              | Patient 3                   | Patient 4                              |
|-----------------------|--|--|-----------------------------|--|
| Age                   | 70 years old                           | 66 years old                           | 53 years old                | 75 years old                           |
| Gender                | Male                                   | Male                                   | Female                      | Male                                   |
| Baseline mRS          | 1                                      | 0                                      | 0                           | 1                                      |
| Baseline NIHSS        | 15                                     | 18                                     | 10                          | 10                                     |
| Occlusion             | Left M1                                | ICA + MCA                              | Right M1                    | BA                                     |
| mTICI                 | 3                                      | 3                                      | 3                           | 3                                      |
| Complications         | No                                     | No                                     | Mild subarachnoid bleeding  | No                                     |
| Anti-platelet therapy | Dual antiplatelet therapy for 3 months | Dual antiplatelet therapy for 3 months | Single antiplatelet therapy | Dual antiplatelet therapy for 3 months |
| NIHSS at discharge    | 6                                      | 7                                      | 0                           | 2                                      |
| 90-days mRS           | 1                                      | 0                                      | 0                           | 2                                      |

effect on the intracranial stenosis, avoiding systemic complications. Nevertheless, there is not enough clinical practice information yet.

We report our initial experience in four patients with acute ICAD-related LVO stroke, treated with ELUTAX “3” DEB, explaining the technical details and the outcome of the procedure, the subsequent management and the clinical evolution of the patients (Table 1).

**Case 1:** A 70-year-old man with previous left hemispheric ischemic stroke treated by primary MT with mRS 1. He experienced a new stroke of uncertain onset due to occlusion of the left M1 segment with a penumbra area in perfusion-CT throughout the MCA territory and a NIHSS of 15.

Under general anesthesia, the puncture of the femoral artery was performed and a 8F introducer was placed. A NeuronMAX 088 sheath (Penumbra Inc, Alameda, CA, US) was positioned in the petrous segment and a Catalyst 6 catheter (Stryker Neurovascular, Kalamazoo, MI, US) was positioned in the cavernous segment of the ICA performing angiographic series (Fig. 1A). The MT was attempted by contact aspiration with an ACE 68 catheter (Penumbra Inc, Alameda, CA, US), which did not achieve the recanalization of the vessel. Then, after several attempts to cross the occlusion, a Traxcess 0.014” microguidewire (MicroVention, Tustin, California, US) could be advanced, and a TrevoPRO 18 microcatheter (Stryker Neurovascular, Kalamazoo, MI, US) was positioned distally in the MCA. This difficulty to cross the occlusion led to suspecting it was a LVO caused by ICAD, so, using an exchange guidewire, the ELUTAX “3” was advanced and an angioplasty was performed directly with an ELUTAX “3” 2.75 × 15 mm DEB. The latter was inflated performing slow gradual increase in pressure inflation, as recommended (1 ATM every 30 s) (Fig. 1B) to reach its nominal pressure of 6 ATM, using a 50% mixture of iodinated contrast and saline (the same solution was used to purge it). In control angiographic series, recanalization of the affected vessel and its branches, mTICI 3, was seen, with persistent severe stenosis in the M1 segment (Fig. 1C). After 24 h, a control brain CT was performed, showing no evidence of ICH, and DAPT was started. The TCD and angio-CT (Fig. 1D) evidenced residual focal stenosis of over 50%. The patient was discharged 16 days later with a NIHSS of 6 points, maintaining DAPT for 3 months. The 90-days mRS was 1. After one year of follow-up, he has not experienced new strokes.

**Case 2:** A 66-year-old man, smoker, with hypertension, dyslipidemia and a baseline mRS of 0 points. The patient experienced an ischemic stroke due to a right MCA occlusion in its proximal M1 segment, with a NIHSS score of 18 points, a plain CT with ASPECTS of 5 points and a perfusion CT with a penumbra area of over a 40% of the MCA territory.

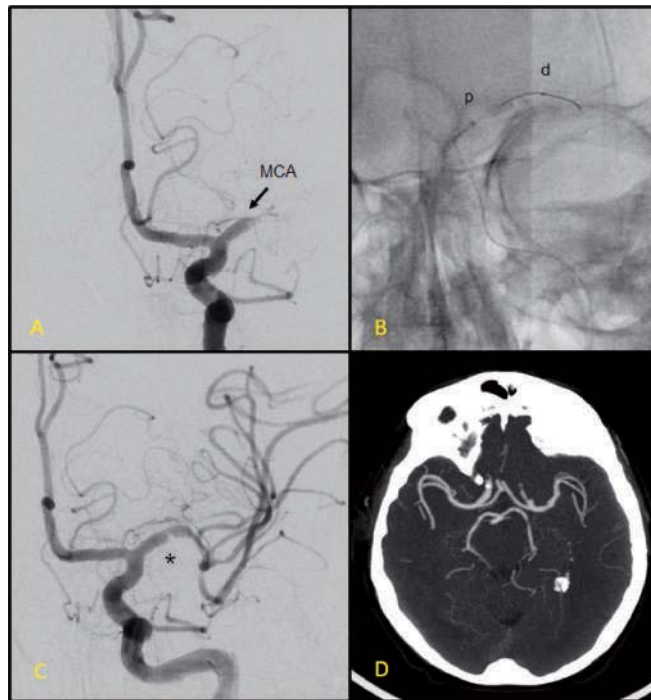
After intravenous fibrinolysis with alteplase, and under general anesthesia, a puncture of the femoral artery was performed, placing a 8F introducer. A NeuronMAX 088 sheath was placed in the petrous segment and a Catalyst 6 catheter was placed in the cavernous segment of the ICA, performing diagnostic angiographic series (Fig. 2A). The MT was attempted by contact aspiration with an ACE 68 catheter achieving

partial revascularization of the vessel due to high-grade stenosis in the terminal segment of the ICA (Fig. 2B), which in control angiographic series progressed to complete occlusion of the MCA. To cross the occlusion area, a Traxcess 0.014” microguidewire and a TrevoPRO 18 microcatheter were used, subsequently replaced with a rapid exchange by an ELUTAX “3” 2.5x10mm balloon. Slow gradual inflation was performed to reach its nominal pressure (6 ATM). Recanalization of mTICI 3 (Fig. 2C) was achieved, with persistent severe stenosis in the origin of the ACA (Fig. 2D). Twenty-four hours later, a control brain CT was performed, without ICH findings, and DAPT was started. The control TCD and the angioCT evidenced residual focal stenosis of 50–69%. The patient was discharged 7 days later with a NIHSS of 7 points, and maintaining DAPT for 3 months. The 90-days mRS was 0, as well as the mRS after one year of follow-up, and he has not experienced new ischemic events.

**Case 3:** A 53-year old woman, with hypertension, type 2 diabetes, dyslipidemia, obesity and previous diagnosis of ICAD in the proximal segment of the right MCA in 2016, under follow-up with TCD and angioCT and with persistent subocclusive stenosis, treated with acenocoumarol and ASA. The patient experienced a stroke of uncertain onset on the right MCA territory, with NIHSS score of 7 points and a perfusion CT with penumbra area throughout this territory.

Under general anesthesia, a puncture of the femoral artery was performed, obtaining angiographic series, which evidenced severe stenosis in the right supraclinoid ICA and the origin of both the ACA and the MCA (Fig. 3A). The proximal segment of the MCA was accessed through a tri-coaxial system comprising a Neuron 6F 90 cm catheter (Penumbra Inc, Alameda, CA, US), a Sofia 5F 115 cm intermediate catheter (MicroVention Inc, Aliso Viejo, CA, US) and an Echelon 0.017” 150 cm catheter (Medtronic, Dublin, Ireland). For intracranial navigation of the system, a Traxcess 0.014” microguidewire was used. The microcatheter exchange was performed using a Traxcess Docking wire adapter (MicroVention Inc, Aliso Viejo, CA, US) of 115 cm, positioning on the supraclinoid ICA stenosis an ELUTAX “3” balloon of 2.5x10 mm (Fig. 3B), and dilating it slowly to its nominal pressure (6 ATM). A Gateway balloon (Stryker Neurovascular, Kalamazoo, MI, US) of 1.5 mm was then progressed to distal M1 segment and three progressive dilations were performed proximally to the origin of the MCA. The final controls evidenced complete recovery of the vascular caliber of the MCA and the ICA (Fig. 3C), with severe residual stenosis in the origin of the ACA. Twenty-four hours later a brain CT was performed, which evidenced a subarachnoid bleeding in the sulci of the right convexity and no signs of restenosis in the angioCT (Fig. 3D). Antiplatelet therapy was started with ASA 100 mg and the patient was discharged with NIHSS of 0, maintaining treatment with simple antiaggregation and removing anticoagulation. The 90-days mRS was 0. After one year of follow-up, asymptomatic restenosis was seen in a control angioCT, starting DAPT, but she did not experience new strokes.

**Case 4:** A 75-year old man, smoker, with hypertension, diabetes and a



**Fig. 1.** A: PRE-ANGIOPLASTY Selective digital subtraction arteriography of the left ICA in anteroposterior view. Occlusion in segment M1 of the MCA. B: ANGIOPLASTY Image of arteriography without subtraction in anteroposterior view. After progressing through the occlusion, the angioplasty balloon is partially inflated, observing its proximal (p) and distal (d) mark. C: POST-ANGIOPLASTY Recanalization of the MCA, with persistent severe focal stenosis in segment M1 (\*). D: CONTROL ANGIOCT. Recanalized MCA with moderate-severe residual stenosis.

baseline mRS 1, who experienced a stroke about 12 h before due to complete occlusion of the BA in its middle third and previous occlusion of right V4, with a NIHSS score of 10 points.

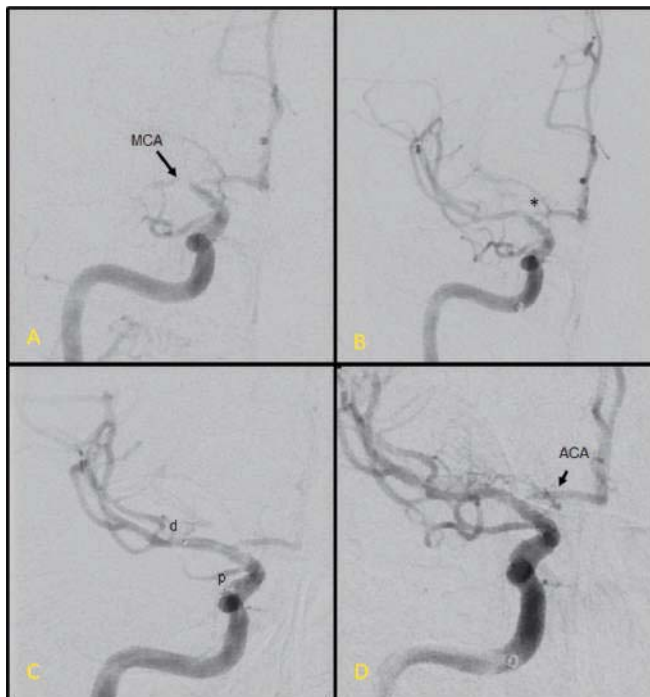
Under general anesthesia, a NeuronMAX 088 sheath was placed in the left V1 and diagnostic angiographic series were performed (Fig. 4A). An attempt was made to perform MT by aspiration with ACE 68 catheter, without achieving any recanalization after two contact aspirations. A Traxcess 0.014" microguidewire was used to cross the occlusion area and, after checking the permeability of the distal branches by contrast injections with a microcatheter, a Tigertriever 4x32 mm stent (Rapid Medical, Yokneam, Israel) was placed. A run was performed together with simultaneous local aspiration (Fig. 4B), achieving the opening of the intracranial stenosis and evidencing a distal thrombus that occluded the left P1 segment (Fig. 4C). An ELUTAX™3" balloon of 3x10 mm was positioned centered in the stenosis and inflated slowly to its nominal pressure (6 ATM), achieving the recovery of the vascular caliber. Then, the stenosis point was crossed with an ACE 68 aspiration device to the level of BA bifurcation. After one contact aspiration, the posterior circulation could be completely recanalized (Fig. 4D). A load of 250 mg intravenous ASA was administered during the procedure. Twenty-four hours later, a control brain CT was performed, which evidenced infarction in the right hemiserebellum, with no ICH findings, and DAPT was started. The patient was discharged 7 days later with NIHSS of 2 points. The 90-days mRS

was 2. Ten months after the procedure, he has not experienced neither stenosis nor focal symptoms.

## 2. Discussion

Acute treatment of ICAD-related strokes is still controversial and challenging. Vessel re-occlusion during MT is a common complication, and studies have not demonstrated the superiority of glycoprotein IIb/IIIa inhibitors or angioplasty alone or with self-expanding stents over other treatments. On the other hand, these therapies have an important risk of intracranial bleeding, vessel rupture or stent thrombosis. Therefore, new therapies have been searched for, some of them following the results of coronary flow studies, since coronary artery occlusions are usually caused by local thrombosis of atherosclerotic vessels, with a similar mechanism of intracranial atherosclerotic-related occlusions.

Considering primary percutaneous transluminal coronary angioplasty has the highest recommendation in acute myocardial infarction, and the complications related to stent-retriever MT, Yang et al. have compared primary angioplasty and/or stenting with conventional stent-retriever MT. They have reported favorable functional outcomes and lower asymptomatic ICH rates in the angioplasty and/or stenting group [13]. However, most of the patients in this group had an ICA occlusion and better collateral flow. Hence, these results may not be applicable to MCA occlusions.



**Fig. 2.** A: PRE-TREATMENT Selective digital subtraction arteriography of the right ICA in anteroposterior view. Occlusion in the origin of the MCA. B: POST-ASPIRATION. After a run of mechanical aspiration, severe focal stenosis was seen in the terminal segment of the ICA (\*), that affects the origin of the MCA and ACA. C: ANGIOPLASTY Angiographic series following angioplasty with ELUTAX “3” balloon in segment M1 of the MCA and terminal segment of the right ICA. The balloon is deflated and the distal (d) and proximal (p) mark can be seen. D: POST-ANGIOPLASTY Complete recovery of the MCA caliber, with persistent severe stenosis in the origin of the ACA.

Bradley et al. have proposed the use of balloon-mounted stents as an alternative to self-expanding conventional stents, due to their advantage of a swift single pass. Nevertheless, in their series an important percentage of patients suffered *peri*-procedural complications, including symptomatic ICH and stent thrombosis. Their results were, therefore, worse than those seen for patients undergoing MT for LVO secondary to embolic disease [14].

In randomized studies on coronary flow, a reduction in the restenosis and clinical event rates has been shown with the use of paclitaxel-eluted balloons compared to conventional balloons [15]. Thus, the use of these devices in the intracranial circulation has been considered for the treatment of chronic ICAD, including the ELUTAX “3” DEB.

As we know, there is evidence of the use of other DEBs as secondary prevention in patients with symptomatic ICAD [16]. Gruber et al. have been the first to compare ELUTAX “3” to the Wingspan stent (Stryker Neurovascular, Kalamazoo, MI, US) in symptomatic ICAD, obtaining better outcomes in terms of recurrence of stroke/TIA or restenosis, without any statistically significant differences in evolution, complications or mortality [17]. However, to our knowledge, our patients are the first patients with ICAD-related LVO strokes treated with the ELUTAX “3” DEB in an acute phase.

Our preliminary experience with these four cases shows that it is an easy navigation device, which reduces intimal hyperplasia, the main cause of restenosis in patients with ICAD. A tri-axial support system was used in all cases since the initial intention was to perform a conventional MT. Then, once the diagnosis of ICAD-related stroke was made, a microcatheter was first advanced distal to the lesion to perform an

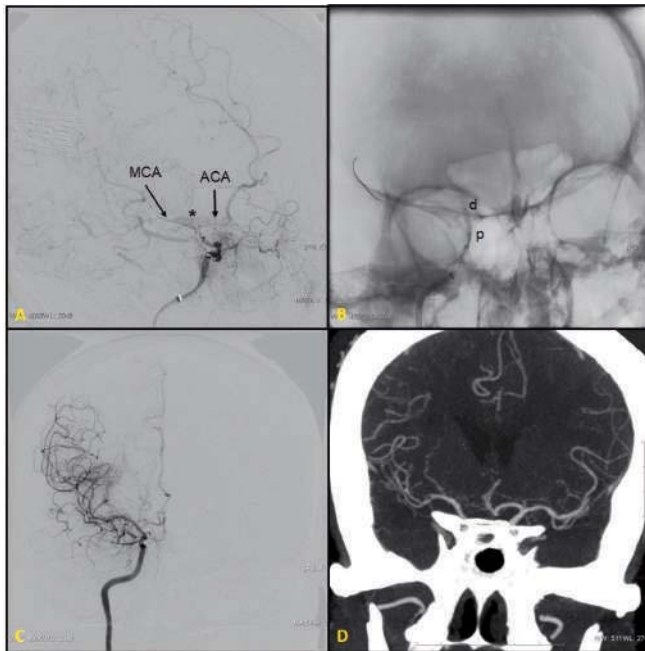
initial angiogram to assess the vascular anatomy of major branch-vessel as well as determine the length of the lesion to be treated. The size and length of the balloon were chosen based on the characteristics of the lesion. The entire lesion length should be covered by the balloon, and the diameter should be smaller than the normal vessel size. Then, over an exchange microguidewire, the Elutax “3” was easily advanced and positioned to cover the stenosis, slowly inflated to its nominal pressure. Besides, once the purge of the balloon is done correctly, the visibility is excellent.

These procedures allowed us to achieve a mTICI 3 recanalization in all the patients, with a residual stenosis inferior to 70% and a good performance status on discharge, which are all of factors of good prognosis to prevent restenosis and future ischemic events. In addition, the only remarkable complication was a mild asymptomatic subarachnoid bleeding in one of the patients. As for mid-term results, the mRS after 90 days for those patients was less than or equal to 2, and after one year of follow-up they have not reported new ischemic events.

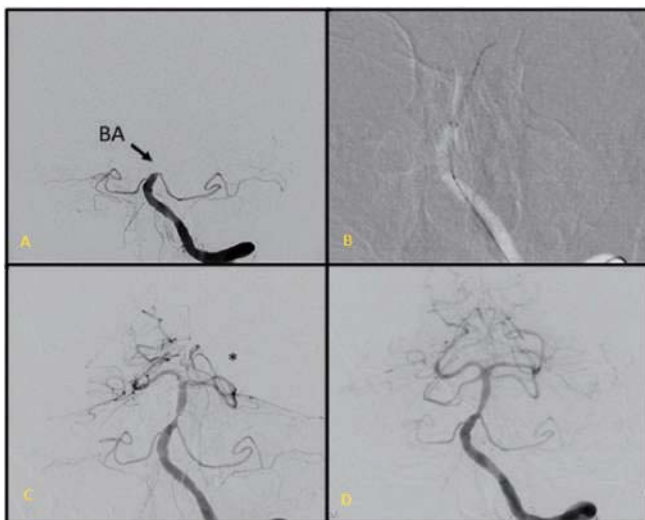
On the other hand, it must be highlighted that, using the Elutax “3” DEB, subsequent DAPT is not required. Thus, in patients receiving alteplase it does not increase the risk of ICH. However, in our case we maintained DAPT for at least three months in three of the patients due to the lack of experience with this new device and because of the persistent, at least 50%, residual stenosis.

### 3. Conclusions

Based on the results described, we consider this might be a therapeutic option to take under consideration in acute LVO secondary to



**Fig. 3.** A: PRE-TREATMENT Selective brain arteriography of the right ICA. Subocclusive stenosis of the supraclinoid ICA with minimum passage of filiform contrast to MCA and ACA. Moyamoya type arteriolar network around the bifurcation (\*). B: ANGIOPLASTY Once the stenosis has been crossed an ELUTAX "3" balloon of 2.5x10 mm is centered in the maximum stenosis point (p, proximal mark; d, distal mark). C: POST-ANGIOPLASTY Recovery of the vascular caliber in the MCA and supraclinoid ICA, with severe residual stenosis of the origin of ACA. D: CONTROL ANGIOCT No restenosis is seen in the segments treated. Adequate compensation of the vascular territory dependent on the right ACA from the left side.



**Fig. 4.** A: PRE-TREATMENT Selective cerebral arteriography of the left vertebral artery. Complete occlusion of the middle third of the BA. B: After performing two contact aspirations, no recanalization was achieved, which increased the suspicion of intracranial stenosis. A Tigertriever stent extractor was placed, centered in the occlusion together with simultaneous aspiration by ACE 68. C: POST-THROMBECTOMY Recanalization of the basilar artery is seen, together with significant stenosis of the middle third due to atheromatous stenosis and distal occlusion of the proximal segment of the left posterior cerebral artery (P1) (\*). D: FINAL CONTROL Complete recanalization of the posterior circulation and recovery of vascular caliber after two angioplasties with ELUTAX "3" coated balloon in the intracranial stenosis of the BA.

ICAD, when MT is not effective or possible. However, further studies with a higher number of patients are required to evaluate the efficacy and safety of this device.

#### 4. Contributorship statement

All the authors from the author list above have contributed to the design and the writing of this manuscript, have revised it critically for important intellectual content, have given the final approval of the version to be published and agree to be accountable for all aspects of the work in ensuring that questions related to the accuracy or integrity of any part of the work are appropriately investigated and resolved.

There are no other contributors to this manuscript.

#### Funding statement

This research received no specific grant from any funding agency in the public, commercial or not-for-profit sectors.

#### CRediT authorship contribution statement

**Blanca Serrano Serrano:** Writing - original draft, Visualization. **Francisco Hernández Fernández:** Writing - review & editing. **Nicolás López Hernández:** Writing - review & editing, Supervision. **Elena Elvira Soler:** Writing - review & editing. **Giorgio Barbieri:** Writing - review & editing. **Juan D. Molina Nuevo:** Writing - review & editing.

#### Declaration of Competing Interest

The authors declare that they have no known competing financial interests or personal relationships that could have appeared to influence the work reported in this paper.

#### Acknowledgements

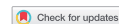The authors of this article would like to acknowledge Dr. Antonio Moreno for his help with the translation of the manuscript.

#### References

- [1] Philip B. Gorelick, Wong Ka Sing, Bae Hee-Joon, K. Pandey Dilip, Large artery intracranial occlusive disease, *Stroke* 39 (8) (2008 Aug 1) 2396–2399.
- [2] C.A. Holmstedt, T.N. Turan, M.I. Chimowitz, Atherosclerotic intracranial arterial stenosis: risk factors, diagnosis, and treatment, *Lancet Neurol.* 12 (11) (2013 Nov) 1106–1114.
- [3] C. Banerjee, M.I. Chimowitz, Stroke caused by atherosclerosis of the major intracranial arteries, *Circ. Res.* 120 (3) (2017 Feb 3) 502–513.
- [4] W.J. Powers, A.A. Rabinstein, T. Ackerson, O.M. Adeoye, N.C. Bambakidis, K. Becker, et al., Guidelines for the early management of patients with acute ischemic stroke: a guideline for healthcare professionals from the American Heart Association/American Stroke Association, *Stroke* 49 (3) (2018) e46–e110.
- [5] C. Tian, X. Cao, J. Wang, Recanalisation therapy in patients with acute ischaemic stroke caused by large artery occlusion: choice of therapeutic strategy according to underlying aetiological mechanism? *Stroke Vasc. Neurol.* 2 (4) (2017 Dec) 244–250.
- [6] C.P. Derdeyn, M.I. Chimowitz, M.J. Lynn, D. Fiorella, T.N. Turan, L.S. Janis, et al., Aggressive medical treatment with or without stenting in high-risk patients with intracranial artery stenosis (SAMMPRIS): the final results of a randomised trial, *Lancet Lond. Engl.* 383 (9914) (2014 Jan 25) 333–341.
- [7] O.O. Zaidat, B.-F. Fitzsimmons, B.K. Woodward, Z. Wang, M. Killer-Oberpfalzer, A. Wakhloo, et al., Effect of a balloon-expandable intracranial stent vs medical therapy on risk of stroke in patients with symptomatic intracranial stenosis: the VISSIT randomized clinical trial, *JAMA* 313 (12) (2015 Mar 24) 1240–1248.
- [8] J.-H. Baek, B.M. Kim, J.H. Heo, D.J. Kim, H.S. Nam, Y.D. Kim, Outcomes of endovascular treatment for acute intracranial atherosclerosis-related large vessel occlusion, *Stroke* 49 (11) (2018 Nov) 2699–2705.
- [9] T. Zhou, T. Li, L. Zhu, M. Wang, Y. He, Q. Shao, et al., Intracranial stenting as a rescue therapy for acute ischemic stroke after stentriever thrombectomy failure, *World Neurosurg.* 120 (2018 Dec) e181–e187.
- [10] D.-H. Kang, Y.-W. Kim, Y.-H. Hwang, S.-P. Park, Y.-S. Kim, S.K. Baik, Instant re-occlusion following mechanical thrombectomy of in situ thromboocclusion and the role of low-dose intra-arterial tirofiban, *Cerebrovasc. Dis. Basel Switz.* 37 (5) (2014) 350–355.
- [11] D.-H. Kang, W. Yoon, S.K. Kim, B.H. Baek, Y.Y. Lee, Y.-W. Kim, et al., Endovascular treatment for emergent large vessel occlusion due to severe intracranial atherosclerotic stenosis, *J. Neurosurg.* 1 (2018 Jun) 1–8.
- [12] S. Zhang, Y. Hao, X. Tian, W. Zi, H. Wang, D. Yang, et al., Safety of intra-arterial tirofiban administration in ischemic stroke patients after unsuccessful mechanical thrombectomy, *J. Vasc. Interv. Radiol. JVIR* 30 (2) (2019 Feb) 141–147 e1.
- [13] D. Yang, M. Lin, S. Wang, H. Wang, Y. Hao, W. Zi, et al., Primary angioplasty and stenting may be superior to thrombectomy for acute atherosclerotic large-artery occlusion, *Interv. Neuroradiol.* 24 (4) (2018 Aug) 412–420.
- [14] B.A. Gross, S.M. Desai, G. Walker, B.T. Jankowitz, A. Jadhav, T.G. Jovin, Balloon-mounted stents for acute intracranial large vessel occlusion secondary to presumed atherosclerotic disease: evolution in an era of supple intermediate catheters, *J. Neurointerventional Surg.* 11 (10) (2019 Oct) 975–978.
- [15] B. Scheller, C. Hehrlein, W. Bocksch, W. Rutsch, D. Haghi, U. Dietz, et al., Treatment of coronary in-stent stenosis with a paclitaxel-coated balloon catheter, *N. Engl. J. Med.* 355 (20) (2006 Nov 16) 2113–2124.
- [16] J. Zhang, X. Zhang, J.-P. Zhang, J. Han, Endovascular recanalisation with drug coated balloon for chronic symptomatic middle cerebral artery total occlusion, *J. Neurointerventional Surg.* 10 (9) (2018 Sep) e24.
- [17] P. Gruber, C. Garcia-Esperon, J. Berberat, T. Kahles, M. Hlavica, J. Anon, et al., Neuro Elutax SV drug-eluting balloon versus Wingspan stent system in symptomatic intracranial high-grade stenosis: a single-center experience, *J. Neurointerventional Surg.* 10 (12) (2018 Dec) e32.



REVIEW



## Device profile of different paclitaxel-coated balloons: Neuro Elutax SV, Elutax '3' Neuro and SeQuent Please NEO for the treatment of symptomatic intracranial high-grade stenosis: overview of their feasibility and safety

Philipp Gruber and Luca Remonda

Department of Neuroradiology, Cantonal Hospital of Aarau, Aarau, Switzerland

### ABSTRACT

**Introduction:** Intracranial atherosclerotic disease (ICAD) is highly prevalent and probably the most common cause of stroke worldwide. Despite best medical treatment (BMT), the rate of recurrent stroke in symptomatic ICAD patients is elevated, especially in those with high-grade stenosis. Thus, alternative treatment options are needed. So far, endovascular ICAD treatment has been considered a second-line therapy. However, recent progress in the endovascular acute stroke treatment challenges this issue. Drug-coated balloon (DCB) – percutaneous transluminal angioplasty (PTA) represents a promising alternative to BMT alone.

**Areas covered:** In this review, current clinical studies on paclitaxel-coated DCB-PTA in symptomatic high-grade ICAD patients will be presented and discussed. Furthermore, technical profile of the different paclitaxel-coated DCB, which has been used for intracranial use (Neuro Elutax SV, Elutax '3' Neuro, and SeQuent Please NEO) are being presented.

**Expert opinion:** Despite limited data and its experimental (off-line) use, DCB-PTA has been demonstrated to be feasible and safe in selected ICAD patients with symptomatic high-grade stenosis. DCB-PTA offers several advantages compared to alternative endovascular therapy option as well as BMT alone. Consequently, DCP-PTA might be a promising candidate for the future armamentarium in ICAD treatment.

### ARTICLE HISTORY

Received 25 September 2019  
Accepted 20 January 2020

### KEYWORDS

Drug-coated balloon; Elutax '3' Neuro; intracranial atherosclerotic disease; Neuro Elutax SV; paclitaxel; percutaneous transluminal angioplasty; ischemic stroke; SeQuent Please NEO

## 1. Introduction

### 1.1. Intracranial atherosclerotic disease – a medical treatment challenge

Intracranial atherosclerotic disease (ICAD) is highly prevalent and is probably the most common cause of stroke worldwide since the incidence in the Asian, Hispanic and African populations is high [1,2]. It has been shown that ICAD patients with high-grade stenosis ( $\geq 70$ –99%) are at increased risk of recurrent stroke [3,4]. Current guidelines recommend an adequate antiplatelet treatment combined with consequent treatment of vascular risk factors such as hypertension, diabetes mellitus, dyslipidemia, and nicotine abuse [5]. Despite this treatment regimen, the stroke recurrence rate remains disappointingly high, as the GESICA or WASID studies have shown [4]. There is therefore a need for other treatment options in symptomatic ICAD patients. The endovascular treatment of ICAD patients has a long tradition and dates back to the early 1980s [6]. Despite promising results from several mono-center studies, case series and cohort studies either using percutaneous transluminal angioplasty (PTA) alone or percutaneous angioplasty with stenting (PTAS), the large-randomized SAMMPRIS trial comparing PTAS with the self-expanding Wingspan stent system (StrykerNeurovascular, Fermont, CA, USA) with aggressive medical treatment failed to show the effectiveness of PTAS in symptomatic ICAD patients [7]. Furthermore, the

VISSIT trial that compared PTAS using the balloon-mounted Pharos Vitesse stent system (Codman&Shurtleff, Raynham, Massachusetts, USA) compared to best medical treatment (BMT) alone was prematurely terminated and demonstrated the inferiority of PTAS in ICAD patients [8]. These results are mainly due to the high peri-procedural complication rate in the intervention arms (14.9% in the SAMMPRIS and 36.2% in the VISSIT trial, respectively) [7,8]. Recently, these data were challenged by the results of the post-marketing, mono-cohort, multi-center WAEVE trial that looked at peri-procedural complications within 3 days after PTS using the Wingspan Stent system demonstrating a complication rate of 2.6% being significantly lower than SAMMPRIS or the VISSIT trial, therefore comparable to BMT alone [9]. These promising results are mainly due to the rigorous selection criteria and the fact that only comprehensive stroke centers with abundant experience in endovascular ICAD treatment could participate in this trial.

### 1.2. Mid- to long-term complications in PTA and PTAS

Besides the above-mentioned limitations there are also mid- to long-term complications in both PTA and PTAS, respectively, concerning the restenosis rate. This issue is well known and has been described in several series for both PTA and PTAS with recurrent stenosis rate of up to 30% [10–12]. The main cause of restenosis is neointimal hyperplasia (NIH).

**Article highlights**

- Intracranial atherosclerotic disease (ICAD) is highly prevalent and probably the most common cause of stroke worldwide.
- Current guidelines recommend the best medical treatment (BMT) as first-line therapy. Despite BMT, the stroke recurrence rate is elevated in symptomatic ICAD patients with high-grade stenosis.
- Drug-coated balloon percutaneous trans-luminal angioplasty (DCB-PTA) might offer an efficient alternative treatment option.
- Despite its current experimental use, DCB-PTA is feasible and safe in well-selected ICAD patients.
- Neuro Elutax SV and SeQuent Please NEO have been proven to be feasible and safe in ICAD patients with symptomatic high-grade stenosis.
- Large randomized trials are needed to prove the concept that DCB-PTA is effective in ICAD patients.
- To our opinion, DCB-PTA has the potential to play an important role in the endovascular treatment of ICAD.

Both PTA and PTAS lead to (micro-) lesions of the endothelium and the intima portion of the vessel wall due to the mechanical stress during dilatation. These lesions induce a complex cascade of repair mechanism that finally results in excessive smooth muscle and connective tissue proliferation. To overcome this major disadvantage of PTA and PTAS, several anti-proliferative, as well as immune-modulatory agents, have been evaluated [13]. The highly lipophilic anti-proliferative microtubule-stabilizer paclitaxel has been proven to be effective inhibitor of NIH *in vitro* as well *in vivo* [14]. Clinical evidence for the efficacy of drug eluted stents (DES) as well as drug-coated balloon (DCB) is mainly derived from the peripheral endovascular field. Feasibility, safety, and efficacy have been widely shown in interventional cardiology studies for both DES and DCB, respectively [15,16]. Recent encouraging results from the Basket Small II trial demonstrated superiority of DCB (SeQuent Please and SeQuent Please NEO) compared to DES *de novo* small coronary artery disease [17].

Currently, data on the use of DES as well as DCB in neurovascular patients are limited. Promising data on DES has been published in the early 2000 [18–21], but the interest on PTAS and PTA dramatically decreased after the negative SAMMPRIS and VISSIT trial [22].

## 2. Drug-coated balloon in the neurovascular field – a potential candidate device for ICAD treatment

Given the high incidence of ICAD worldwide, as well as the high risk of recurrent strokes – especially in ICAD patients with symptomatic high-grade stenosis – there is a need for new treatment concepts in addition to BMT alone [23]. DCB might be a real alternative treatment modality to BMT alone and offers several advantages compared to PTAS [24,25]. PTA in ICAD patients has been shown to be feasible and safe due to the advance of material technology over the last two decades. Furthermore, the introduction of submaximal angioplasty technique that intends to prevent PTA from feared vessel dissection and the so-called ‘snow-plow’ effect (the involuntary occlusion of perforator vessel by plaque dislodgment during PTA) [26] increased peri-procedural safety. In addition,

DCB-PTA enables a positive remodeling of the treated vessel wall and keeps natural vessel vasomotion compared to PTAS. There is no foreign material left in the vessel lumen compared to PTAS, thus preventing long-term inflammatory reactions caused by the foreign material. DCB-PTA leads to a more efficient and homogeneous drug distribution over the treated vessel wall compared to DES that covers only 15% of the vessel lumen with drug due to stent-strut geometry [27]. There are no stent-related limitations for additional treatment. Since there is a low risk of incomplete neointimal healing and delayed endothelialization in DCB-PTA compared to DES [28], the duration of dual antiplatelet therapy (DAPT) could be shortened in patients treated with DCB-PTA compared to patients treated with DES as recommended for cardiac patients with 1 month [29]. Due to the high risk of intracranial hemorrhage in the neurovascular field, long-term and aggressive anti-aggregation should be avoided. Making DCB-PTA an even more attractive treatment option since there are many ICAD patients with additional co-morbidities such as atrial fibrillation. Nevertheless, the post-procedural antiplatelet therapy in DCB-PTA treated patients has to be elucidated for the neurovascular field since there is no data available.

Economically, DCB-PTA might be more cost-effective compared to PTA or PTAS using DES as it has been demonstrated for the endovascular treatment of femoro-popliteal artery disease [30]. Accordingly, providing another advantage of DCB-PTA technique.

The disadvantages of DCB-PTA are the potential early recoil and a larger degree of post-procedural residual stenosis compared to DES.

Currently, all data regarding DCB-PTA in ICAD patients correspond to paclitaxel-coated DCB-PTA systems. To the best of our knowledge, there are no publicly available data concerning other drug-coating, such as Sirolimus – coated balloons.

## 3. Current studies on paclitaxel-coated balloon-PTA in the neurovascular field

In 2018, first reports on DCB-PTA for *de novo* symptomatic high-grade ICAD patients were published (Table 1). We retrospectively compared a cohort of symptomatic high-grade ICAD patients either treated with the first CE-certified DCB for neurovascular use (Neuro Elutax SV) ( $n = 8$ ) or treated with the Wingspan – Stent System ( $n = 11$ ) with a median follow-up of 9.5 and 10.0 months, respectively [31]. The results showed a significantly lower symptomatic and asymptomatic recurrence rate with a lower complication rate in DCB-treated patients compared to Wingspan stent patients. Another study reported excellent feasibility and safety on a mono-cohort of 10 symptomatic ICAD patients treated with the SeQuent Please NEO (b.braun, Melsungen, Germany) DCB – a latest coronary DCB-PTA system [32]. In both studies, submaximal angioplasty technique was performed for balloon deployment. Of note, we did not perform any pre-dilatation using a conventional balloon PTA system. A third Chinese study on symptomatic high-grade *de novo* ICAD patients demonstrated good results in 30 patients treated with SeQuent Please (b. braun Melsungen, Germany) – the previous DCB-PTA model of

**Table 1.** Summary of current studies of paclitaxel-coated balloon (pDCB)-PTA in symptomatic high-grade stenosis.

| Publication                     | N. of DCB treated patients | Type of study   | DCB-PTA system                     | Follow-up period in months | DCB deployment technique        | Post-procedural stenosis degree | Peri-procedural complications | Asymptomatic restenosis | Symptomatic restenosis |
|---------------------------------|----------------------------|---|------------------------------------|----------------------------|---------------------------------|---------------------------------|-------------------------------|-------------------------|------------------------|
| Gruber P. et al. JNIS 2018 [31] | 8                          | Retrospective comparison of pDCB-PTA vs Wingspan-PTAS | Neuro Elutax SV (Aachen Resonance) | 9.5                        | Submaximal angioplasty          | 37.5% (20–60)                   | 0                             | 1 (13%)                 | 0                      |
| Gruber P. et al. JNIS 2018 [32] | 10                         | Retrospective monocohort study                        | Sequent Please NEO (b.braun)       | 3                          | Predilatation with conventional | 50% (45–53)                     | 0                             | 0                       | 0                      |
| Han J et al. JNIS 2018 [33]     | 30                         | Retrospective monocohort study                        | SeQuent Please (b. braun)          | 9.8                        | Submaximal angioplasty          | 20% (10–40)                     | 2 (6.5%)                      | 1 (3.5%)                | 0                      |

pDCB, paclitaxel drug-coated balloon; N., number; PTA, percutaneous transluminal angioplasty; PTAS, percutaneous transluminal angioplasty with stenting.

the SeQuent Please NEO [33]. In contrast to our reported practice, all stenoses were pre-dilated with a Gateway balloon.

Recently, another study demonstrated the successful use of paclitaxel-coated DCB-PTA (SeQuent Please, b.braun, Melsungen, Germany) in 14 patients with non-acute total occlusion of the middle cerebral artery. In contrast to our studies, DCB-PTA was performed after predilatation with a conventional balloon [34]. DCB-PTA has also been successfully used in intracranial restenosis of ICAD patients initially treated with PTAS [35].

Current data suggest that the use of DCB-PTA in selected patients with symptomatic high-grade intracranial stenosis is safe and feasible. However, further randomized studies are required to also prove its efficacy.

## 4. Profile of the different paclitaxel-coated balloons

### 4.1. Neuro Elutax SV

One retrospective study reported on the use of the Neuro Elutax SV (Aachen Resonance, Aachen, Germany) being the first CE-certified DCB for neurovascular purpose [36]. Neuro Elutax SV DCB is a 360-degree Paclitaxel-coated DCB (2.2 µg/mm<sup>2</sup>) consisting of a complex three-layer matrix that allows uniform drug release and prevents from the rubbing effect – the friction of losing Paclitaxel during the passage throughout the body vessels by a seal layer. Additionally, there is a target deposition modus (TDM) ensuring that paclitaxel will only be released at a certain inflation pressure (6 atm) and only when there is contact to the vessel. The recommended balloon inflation time is 30 s. In certain circumstances, we extend it to a maximum of 60 s. There is no pre-dilation needed.

The Neuro Elutax has a 0.017-inch tip profile and is available from length sizes of 10 to 30 mm as well as diameters ranging from 1.5 to 4 mm. The working length is limited to 135 cm, which has to be extended at least to 150 cm to reach more distant lesions. Neuro Elutax has a 5F-guiding catheter as well as 0.014-inch guidewire compatibility. This DCB is navigable, flexible and offers a good pushability. This DCB-PTA system has a hydrophilic shaft coating. In our hands, Neuro Elutax SV has proven to be effective in more proximal

lesions. However, in distal and very tortuous vessels it requires some technical improvements since the balloon is to a certain amount rigid and the PTA-catheter system is only available in working length of 135 cm. Unfortunately, the CE certificate has expired and is currently under reevaluation.

### 4.2. Elutax '3' Neuro

The Elutax '3' Neuro (AR Baltic Medical, Vilnius, Lithuania) DCB-PTA system is currently the only available CE-certified DCB-PTA system for neurovascular use representing a kind of successor to the Neuro Elutax SV [37]. This DCB has a modified drug-coating surface layer with a three-dimensional dextran-paclitaxel formation. This specific coating intends to minimize drug-loss during the DCB navigation through the body vessels. Similar to Neuro Elutax SV, this possesses also a TDM, allowing Paclitaxel to be released only upon contact with the vessel wall and at a certain balloon inflation pressure (6 atm). The recommended balloon inflation time is 15 s and thus shorter compared to Neuro Elutax SV (30 s) or SeQuent Please NEO (30 s). Similar to Neuro Elutax SV no pre-dilation is necessary.

The Elutax '3' Neuro is compatible with 5F guiding catheters and 0.014-inch guidewires. The Elutax '3' Neuro is in various balloon sizes available: nominal diameter from 1.5 to 4.0 mm as well as nominal balloon length from 10 mm to 40 mm. Furthermore, this DCB-PTA system has a hydrophilic shaft coating and is also available in a working length of 144 cm that represents an advantage to reach distal lesions. Currently, clinical data of Elutax '3' Neuro are very limited.

### 4.3. SeQuent Please NEO

SeQuent Please NEO (b.braun, Melsungen, Germany) is a latest-generation coronary DCB-PTA [38]. The coating of SeQuent Please NEO consists of a complex, polymer-free Paclitaxel and lopromide matrix (3 µg/mm<sup>2</sup>). Similarly to Neuro Elutax SV, SeQuent Please NEO enables a rapid drug transfer from the balloon matrix to the vessel wall within 30 s. No pre-dilation is needed.

This DCB is also available in various balloon sizes. Therefore, the balloon length ranges from 10 to 40 mm and the balloon

diameter from 2.0 to 4.0 mm. SeQuent Please NEO is compatible with 5F-guiding catheters as well as 0.014-inch guidewires. This DCB-PTA has a hydrophilic shaft coating and the working length is up to 145 cm, which enables reaching more distant lesions. The navigability, the flexibility, and pushability of this DCB are good. In our hands, more distant lesions as well as more tortuous vessel could be treated using the SeQuent Please NEO DCP-PTA system. Additionally, the SeQuent Please NEO has recently proven its efficacy in small ( $\leq 3$  mm) coronary artery disease [17].

## 5. General technical considerations

DCB-PTAs are usually performed under general anesthesia. Prior to the intervention, patients have to be under DAPT (aspirin and clopidogrel). Activated clotting time (ACT) test is performed and body weight-adjusted bolus of intravenous heparin is given prior to the procedure.

Intervention is recommended to be performed on a biplane angiography system. We prefer to gain access via the right common femoral artery using a 7F long-sheath. Rarely is a brachial access used for DCB-PTA – especially in posterior circulation stenosis – but this has so far been without any clinical evidence.

Prior to the intervention, we perform a four-vessel angiogram to assess the general vessel conditions and in particular the targeted vessel lesions. Under fluoroscopic guidance, we prefer to advance a 6F-guiding catheter for the anterior circulation in the cervical segment of the internal carotid artery and for the posterior circulation in the proximal segment of the subclavian artery. The targeted lesion will be explored using a 0.014-inch guidewire. The tip of the guidewire will be positioned distal to the lesion. In monorail technique, the DCB-PTA system will be advanced and precisely centered over the target lesion. We do not perform pre-dilatation and we do not use any kind of protection device. During the angioplasty maneuver, the DCP will be slowly inflated performing submaximal angioplasty technique [26], thus preventing from dissection and perforator branch occlusions ('snow-plow' effect). Before deflation, the DCB stayed submaximally inflated for 30 s. We do always a control angiogram after angioplasty to assess the immediate effect of DCB. If it is needed, we repeat the DCB-PTA maneuver.

Fearful adverse events of the DCB-PTA technique are early recoil of the stenosis that would need additional DCB-PTA runs or bailout stenting, as well as dissection of the vessel or distant embolic ischemic events or perforator ischemic events due to mechanical manipulation of the atherosclerotic lesion [39]. Thus, submaximal angioplasty technique intends to diminish these adverse events as shown by Dumont et al. with a 5% major periprocedural complication rate [26]. But, as already stated by McTaggart, a problem of DCB-PTA will be the balance of submaximal angioplasty and the attempt of whole drug coverage of the vessel wall [25], leading to a less effective drug delivery and a potential higher restenosis rate.

Besides these potential major adverse events of DCB-PTA, generic complications of endovascular therapy such as access site complications (i.e. groin hematoma around 1–9%,

dissection, fistula) contrast agent reaction as well as allergic reactions can occur [40].

## 6. Conclusion

Given the high incidence of ICAD worldwide and the high risk of stroke recurrence despite BMT alone, there is a need for alternative treatment options. Recent data suggested that DCB-PTA using a paclitaxel-coated DCB is feasible and safe in selected ICAD patients with symptomatic high-grade stenosis. Therefore, DCB-PTA might be a promising candidate for the future endovascular treatment alternative in patients with symptomatic high-grade stenosis.

Of note, these first clinical experiences of DCB-PTA in symptomatic ICAD patients are still rather preliminary and has to be currently regarded as experimental. However, given the promising results and high potential of this technique, more research on that topic should be carried out in order to strengthen the evidence of the efficacy of that technique. Thus, large randomized controlled trials should be prompted to prove the efficacy of DCP-PTA in this setting.

## 7. Expert opinion

These first studies on DCB-PTA show feasibility and safety in patients with symptomatic high-grade ICAD. Since the rapid technological and clinical advances in endovascular acute stroke treatment in the last decade, there is a growing interest on ICAD treatment. However, the dogma of conservative treatment of ICAD patients as first-line therapy might only be challenged if the efficacy of DCB-PTA is proven. Therefore, large randomized studies are needed to clarify this important question. In view of the positive results of the WAEVE trial, it might be realistic to expect that endovascular ICAD treatment will regain popularity. The key areas are the technological improvement of DCB-PTA systems to adapt to the specific needs of the neurovascular field. An important issue is the flexibility of the DCB that facilitates the navigability of these DCBs. Further, the working lengths for the DCB-PTA systems have to be adapted for intracranial use, i.e. preferably longer than  $\geq 145$  cm.

As certain concerns have recently been raised about paclitaxel-coated devices, alternative coating strategies such as other neointimal antiproliferative drugs (e.g. Sirolimus, Zotarolimus, or Everolimus) and coating matrices for intracranial application need to be evaluated. In addition, little data are available to date on the safety of drug-coated devices in brain tissue. Further pre-clinical and clinical data are needed.

Future research could help establish DCB-PTA as a real treatment option for the neurovascular field – especially for ICAD. In addition, this research will contribute to a better understanding of the mechanism effect of DCB treatment in the cerebral vasculature and improve the clinical selection of patients. Therefore, next trials in this area should answer the question whether DCB-PTA in symptomatic ICAD patients will be efficient. We believe – given the high prevalence of ICAD and the high rate of stroke recurrence despite the BMT – that endovascular procedures for the treatment of

ICAD patients will regain popularity. Since DCB-PTA treatment in ICAD patients is still experimental in nature, it remains to be elucidated whether DCB-PTA – especially paclitaxel-coated DCB – will become established as a standard treatment in 5 years. Nevertheless, the DCB-PTA technique is a very promising candidate for the future endovascular armamentarium of ICAD treatment.

### 7.1. Five-year view

Due to the high incidence of ICAD worldwide (particularly in Asia) and the additional high risk of recurrent ischemic events despite BMT, alternative treatments are needed for symptomatic ICAD patients. Despite the currently rather experimental character of DCB-PTA in symptomatic ICAD patients, we believe that DCB-PTA will be a real treatment option and accordingly a promising candidate for the future armamentarium of ICAD treatment. However, it might take some time before the concerns about endovascular therapy in ICAD patients are partially or completely resolved. However, DCB-PTA offers several advantages over PTAS, such as no foreign bodies remaining in the vascular lumen, uniform drug coverage of the entire vessel lumen, positive remodeling, and even a shorter DAPT duration.

Of course, despite the promising results of several small studies, large randomized controlled trials are mandatory to shed light on the effectiveness of this DCP-PTA technique in ICAD patients. In addition, the current DCB-PTA systems require additional modifications in navigability, pushability and working length in order to adapt these systems perfectly to the specific needs of the neurovascular field, since the vessels are usually tortuous and technically demanding. There is also a need to define who among symptomatic ICAD patients will benefit most from such endovascular therapy. Possibly symptomatic ICAD patients with hemo-dynamically relevant stenoses as well as patients with unstable plaques could be good candidates for this endovascular treatment [1].

In conclusion, preliminary data have demonstrated the feasibility and safety of DCB-PTA in small cohort studies. Despite its current rather experimental character, DCB-PTA offers several advantages over PTAS and BMT alone, hence DCB represents a promising candidate for the future ICAD treatment.

### Funding

This paper was not funded.

### Declaration of interest

The authors have no relevant affiliations or financial involvement with any organization or entity with a financial interest in or financial conflict with the subject matter or materials discussed in the manuscript. This includes employment, consultancies, honoraria, stock ownership or options, expert testimony, grants or patents received or pending, or royalties.

### Reviewer disclosures

Peer reviewers on this manuscript have no relevant financial or other relationships to disclose.

### Funding

This paper was not funded.

### References

**Papers of special note have been highlighted as either of interest (+) or of considerable interest (++) to readers.**

1. Bang OY. Intracranial atherosclerosis: current understanding and perspectives. *J Stroke*. 2014;16(1):27–35.
2. Vellimana AK, Ford AL, Lee JM, et al. Symptomatic intracranial arterial disease: incidence, natural history, diagnosis, and management. *Neurosurg Focus*. 2011;30(6):E14.
3. Chimowitz MI, Lynn MJ, Howlett-Smith H, et al. Comparison of warfarin and aspirin for symptomatic intracranial arterial stenosis. *N Engl J Med*. 2005;352(13):1305–1316.
4. Mazighi M, Tanasescu R, Ducrocq X, et al. Prospective study of symptomatic atherothrombotic intracranial stenoses: the GESICA study. *Neurology*. 2006;66(8):1187–1191.
5. Powers WJ, Rabinstein AA, Ackerson T, et al. 2018 guidelines for the early management of patients with acute ischemic stroke: a guideline for healthcare professionals from the American heart association/ American stroke association. *Stroke*. 2018;49(3):e46–e110.
6. Sundt TM Jr, Smith HC, Campbell JK, et al. Transluminal angioplasty for basilar artery stenosis. *Mayo Clin Proc*. 1980;55(11):673–680.
7. Chimowitz MI, Lynn MJ, Derdeyn CP, et al. Stenting versus aggressive medical therapy for intracranial arterial stenosis. *N Engl J Med*. 2011;365(11):993–1003.
8. Zaidat OO, Fitzsimmons BF, Woodward BK, et al. Effect of a balloon-expandable intracranial stent vs medical therapy on risk of stroke in patients with symptomatic intracranial stenosis: the VISTA randomized clinical trial. *JAMA*. 2015;313(12):1240–1248.
9. Alexander MJ, Zauner A, Chaloupka JC, et al. WAVE trial final results in 152 on-label patients. *Stroke*. 2019;50(4):889–894.
10. Marks MP, Wojak JC, Al-Ali F, et al. Angioplasty for symptomatic intracranial stenosis: clinical outcome. *Stroke*. 2006;37(4):1016–1020.
11. Wojak JC, Dunlap DC, Hargrave KR, et al. Intracranial angioplasty and stenting: long-term results from a single center. *AJNR Am J Neuroradiol*. 2006;27(9):1882–1892.
12. Wolfe TJ, Fitzsimmons BF, Hussain SI, et al. Long term clinical and angiographic outcomes with the Wingspan stent for treatment of symptomatic 50–99% intracranial atherosclerosis: single center experience in 51 cases. *J Neurointerv Surg*. 2009;1(1):40–43.
13. Papafakis MI, Chatzizisis YS, Naka KK, et al. Drug-eluting stent restenosis: effect of drug type, release kinetics, hemodynamics and coating strategy. *Pharmacol Ther*. 2012;134(1):43–53.
14. Axel DI, Kuner W, Goggelmann C, et al. Paclitaxel inhibits arterial smooth muscle cell proliferation and migration in vitro and in vivo using local drug delivery. *Circulation*. 1997;96(2):636–645.
15. Jackson D, Tong D, Layland J. A review of the coronary applications of the drug coated balloon. *Int J Cardiol*. 2017;226:77–86.
16. Gao L, Chen YD. Application of drug-coated balloon in coronary artery intervention: challenges and opportunities. *J Geriatr Cardiol*. 2016;13(11):906–913.
17. Jeger RV, Farah A, Ohlow MA, et al. Drug-coated balloons for small coronary artery disease (BASKET-SMALL 2): an open-label randomised non-inferiority trial. *Lancet*. 2018;392(10150):849–856.



18. Gupta R, Al-Ali F, Thomas AJ, et al. Safety, feasibility, and short-term follow-up of drug-eluting stent placement in the intracranial and extracranial circulation. *Stroke*. 2006;37(10):2562–2566.
19. Abou-Chebl A, Bashir Q, Yadav JS. Drug-eluting stents for the treatment of intracranial atherosclerosis: initial experience and midterm angiographic follow-up. *Stroke*. 2005;36(12):e165–168.
20. Vajda Z, Aguilar M, Göhringer T, et al. Treatment of intracranial atherosclerotic disease with a balloon-expandable paclitaxel eluting stent: procedural safety, efficacy and mid-term patency. *Clin Neuroradiol*. 2012;22(3):227–233.
21. Kurre W, Aguilar-Perez M, Fischer S, et al. Solving the issue of restenosis after stenting of intracranial stenoses: experience with two thin-strut drug-eluting stents (DES)-taxus element and resolute integrity. *Cardiovasc Intervent Radiol*. 2015;38(3):583–591.
22. Zaidat OO, Castonguay AC, Nguyen TN, et al. Impact of SAMMPRIS on the future of intracranial atherosclerotic disease management: polling results from the ICAD symposium at the international stroke conference. *J Neurointerv Surg*. 2014;6(3):225–230.
23. Luo J, Wang T, Gao P, et al. Endovascular treatment of intracranial atherosclerotic stenosis: current debates and future prospects. *Front Neurol*. 2018;9:666.
  - **Excellent review of the different endovascular treatment modalities in ICAD patients.**
24. Tesfamariam B. Local arterial wall drug delivery using balloon catheter system. *J Control Release*. 2016;238:149–156.
25. McTaggart RA, Marks MP. The case for angioplasty in patients with symptomatic intracranial atherosclerosis. *Front Neurol*. 2014;5:36.
  - **Excellent review on PTA in ICAD patients presenting the whole topic of angioplasty.**
26. Dumont TM, Sonig A, Mokin M, et al. Submaximal angioplasty for symptomatic intracranial atherosclerosis: a prospective phase I study. *J Neurosurg*. 2016;125(4):964–971.
27. Hwang CW, Wu D, Edelman ER. Physiological transport forces govern drug distribution for stent-based delivery. *Circulation*. 2001;104(5):600–605.
28. Pfisterer M, Brunner-La Rocca HP, Buser PT, et al. Late clinical events after clopidogrel discontinuation may limit the benefit of drug-eluting stents: an observational study of drug-eluting versus bare-metal stents. *J Am Coll Cardiol*. 2006;48(12):2584–2591.
29. Kleber FX, Rittger H, Bonaventura K, et al. Drug-coated balloons for treatment of coronary artery disease: updated recommendations from a consensus group. *Clin Res Cardiol*. 2013;102(11):785–797.
30. Katsanos K, Geisler BP, Garner AM, et al. Economic analysis of endovascular drug-eluting treatments for femoropopliteal artery disease in the UK. *BMJ Open*. 2016;6(5):e011245.
31. Gruber P, Garcia-Esperon C, Berberat J, et al. Neuro Elutax SV drug-eluting balloon versus Wingspan stent system in symptomatic intracranial high-grade stenosis: a single-center experience. *J Neurointerv Surg*. 2018;10(12):e32.
  - **First publication on DCB-PTA in ICAD patients with high-grade stenosis comparing the first CE-certified DCB-PTA system for neurovascular use to the Wingspan stent system.**
32. Gruber P, Braun C, Kahles T, et al. Percutaneous transluminal angioplasty using the novel drug-coated balloon catheter SeQuent Please NEO for the treatment of symptomatic intracranial severe stenosis: feasibility and safety study. *J Neurointerv Surg*. 2019;11(7):719–722.
  - **Monochort study on on DCB-PTA in ICAD patients with high-grade stenosis showing feasibility and safety using the DCB-PTA catheter Sequent Please NEO.**
33. Han J, Zhang J, Zhang X, et al. Drug-coated balloons for the treatment of symptomatic intracranial atherosclerosis: initial experience and follow-up outcome. *J Neurointerv Surg*. 2019;11(6):569–573.
  - **Monochort study of 30 ICAD patients treated with the DCB-PTA catheter Sequent Please after predilatation.**
34. Zheng M, Song Y, Zhang J, et al. Endovascular recanalization of non-acute symptomatic middle cerebral artery total occlusion and its short-term outcomes. *Front Neurol*. 2019;10:484.
35. Vajda Z, Guthe T, Perez MA, et al. Neurovascular in-stent stenoses: treatment with conventional and drug-eluting balloons. *AJNR Am J Neuroradiol*. 2011;32(10):1942–1947.
36. Aachen Resonance. Neuro Elutax. [cited 2019 Sept 22]. Available from: [http://www.1amedical.org/wp-content/uploads/2014/04/Elutax\\_SV\\_NEURO\\_Broschüre](http://www.1amedical.org/wp-content/uploads/2014/04/Elutax_SV_NEURO_Broschüre)
37. AR Baltic Medical. Elutax “3” Neuro. [cited 2019 Sept 22]. Available from: <http://www.arbalticmedical.com/products>
38. b.braun. SeQuent Please NEO. [cited 2019 Sept 22]. Available from: <https://www.bbraun.com/en/products/b2/sequent-please-neo.html>
39. Cloft HJ, Lynn MJ, Feldmann E, et al. Risk of cerebral angiography in patients with symptomatic intracranial atherosclerotic stenosis. *Cerebrovasc Dis*. 2011;31(6):588–591.
40. Wong JM, Ziewacz JE, Panchmatia JR, et al. Patterns in neurosurgical adverse events: endovascular neurosurgery. *Neurosurg Focus*. 2012;33(5):E14.



## ORIGINAL RESEARCH

# Neuro Elutax SV drug-eluting balloon versus Wingspan stent system in symptomatic intracranial high-grade stenosis: a single-center experience

Philipp Gruber,<sup>1,2</sup> Carlos Garcia-Esperon,<sup>2</sup> Jatta Berberat,<sup>1</sup> Timo Kahles,<sup>2</sup> Martin Hlavica,<sup>1</sup> Javier Anon,<sup>1</sup> Michael Diepers,<sup>1</sup> Krassen Nedeltchev,<sup>2</sup> Luca Remonda<sup>1</sup>

<sup>1</sup>Department of Neuroradiology, Cantonal Hospital, Aarau, Switzerland

<sup>2</sup>Department of Neurology, Cantonal Hospital, Aarau, Switzerland

## Correspondence to

Dr Philipp Gruber, Department of Neuroradiology, Cantonal Hospital, Aarau 5001, Switzerland; philipp.gruber@ksa.ch

Received 13 December 2017

Revised 1 March 2018

Accepted 5 March 2018

## ABSTRACT

**Background** Intracranial atherosclerotic disease is a well-known cause of ischemic stroke. Following the SAMMPRIS trial, medical treatment is favored over stenting. Drug-eluting balloons (DEB) are widely used in coronary angioplasty, showing better results than bare-surface balloons. There is little evidence of DEB employment in intracranial stenosis, especially of paclitaxel-eluted balloons (pDEB). The Neuro Elutax SV (Aachen Resonance) is the first CE certified pDEB for intracranial use.

**Objective** To compare pDEB Neuro Elutax SV (ElutaxDEB) with the Wingspan/Gateway stent system (WingspanStent).

**Materials and methods** A single-center, open-label, retrospective cohort study of 19 patients with symptomatic atherosclerotic intracranial high-grade stenosis treated with either ElutaxDEB or WingspanStent from a tertiary stroke center in Switzerland.

**Results** Eight patients (42%) received ElutaxDEB. Median clinical follow-up was 10 months for the WingspanStent and 9.5 months for ElutaxDEB ( $P=0.36$ ). No differences were found in the clinical baseline characteristics, with a median stenosis grade of 80% for the WingspanStent and 81% for the ElutaxDEB ( $P=0.87$ ). The compound endpoint 'ischemic re-event and/or restenosis' was significantly lower for ElutaxDEB (13% vs 64%;  $P=0.03$ , OR 0.08 (95% CI 0.007 to 0.93;  $P=0.043$ ) than for the WingspanStent.

**Conclusions** The ElutaxDEB may be a promising alternative treatment for patients with symptomatic high-grade intracranial stenosis showing a significantly lower rate of ischemic re-events or restenosis in comparison with the WingspanStent-treated patients with a similar safety profile. Further studies will be needed to definitively elucidate the role of pDEB in the management of symptomatic intracranial high-grade stenosis.

## INTRODUCTION

Intracranial atherosclerotic disease (ICAD) is a well-known cause of stroke and is responsible for approximately 5–10% of all strokes and up to 50% in the Asian population, with an estimated 1-year stroke-free survival rate of 88%.<sup>1</sup> Despite best medical care, the annual risk of recurrent stroke in symptomatic ICAD is around 9–12%.<sup>2</sup> Therefore, ICAD has to be regarded as a serious medical condition with a high risk of strokes.<sup>27</sup> order to

improve the poor outcome in ICAD, endovascular revascularization using percutaneous transluminal angioplasty with stenting (PTAS) was developed in the 2000s.<sup>3,4</sup> As a result of the SAMMPRIS trial,<sup>2</sup> medical treatment rather than stenting is regarded as first-line therapy because of the high incidence of periprocedural complications (14.7%).<sup>5</sup> Restenosis is an additional major drawback in stent-treated patients, with a recurrence rate of up to 34%. In the post-SAMMPRIS era, there is still a debate about stenting as a possible alternative treatment,<sup>6–8</sup> because despite best medical treatment recurrence rates in symptomatic high-grade stenosis are still considerable.

Following the first randomized clinical trial (RCT) in 2006,<sup>9</sup> recanalization using drug-eluting balloons (DEB) became a well-established technique in coronary angioplasty. However, there is little evidence for the deployment of DEB in ICAD. Several single-center case series have shown the technical feasibility and safety of different drug-eluting stents or DEB.<sup>10–13</sup> Several different DES are available, such as Cipher (Cordis, Miami Lakes, Florida, USA), Taxus Express (Boston Scientific, Natick, Massachusetts, USA) or the Endeavor (Medtronic, Minneapolis, Minnesota, USA), which are not primarily designed for neurovascular procedures and therefore considered off-label use.<sup>14</sup> The Neuro Elutax SV (Aachen Resonance) is a CE certified, hydrophilic balloon—specifically designed for neurovascular application—with an even 360° coating of 2.2 µg/mm<sup>2</sup> paclitaxel, a highly hydrophilic anticancer drug (figure 1).

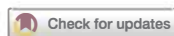The aim of this study was to assess the feasibility, safety, and efficacy of PTA/Neuro Elutax SV DEB compared with PTAS using the WingspanStent system in patients with high-grade ICAD.

## MATERIALS AND METHODS

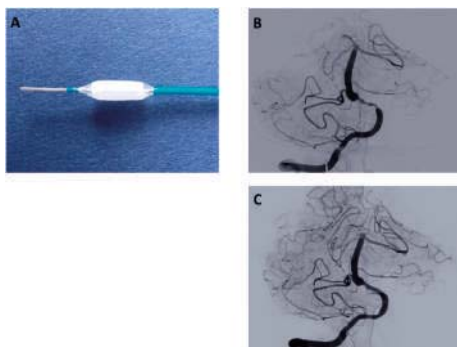
## Patient selection

This retrospective study with an open-label cohort design was carried out at a tertiary stroke center and approved by the local ethic committee.

We initially identified 40 patients with symptomatic intracranial high-grade stenosis who had been treated endovascularly at our institution between January 2009 and September 2016. Endovascular treatment was indicated in patients with symptomatic high-grade intracranial artery stenosis ( $\geq 70\%$  in conventional cerebral angiography) with



**To cite:** Gruber P, Garcia-Esperon C, Berberat J, et al. *J NeuroInterv Surg* Epub ahead of print: [please include Day Month Year]. doi:10.1136/neurintsurg-2017-013699



**Figure 1** (A) Neuro Elutax SV balloon catheter—CE certified—specifically designed for neurovascular applications, with a 360° coating of paclitaxel, a common anticancer drug inhibiting intimal hyperplasia. (B,C) Illustrative case of a patient with a symptomatic right-sided V4 segment 70% stenosis of the vertebral artery treated with the Neuro Elutax SV; before (B) and after (C) procedural cerebral angiography. A reduction of stenosis from 70% to 20% was achieved.

recurrent or progressive stroke/transient ischemic attack (TIA) despite medical treatment. Most patients had at least one platelet inhibitor or oral anticoagulant and received high-dose statins. Furthermore, lifestyle modification and/or drug treatment was established for reduction of risk factors for secondary stroke prevention.

All eligible patients had to be over 18 years and were recanalized either with PTA with Neuro Elutax SV paclitaxel DEB or PTAS using the well-described and approved Wingspan stent system consisting of the WingspanStent and Gateway balloon. Patients treated with other stent systems or other device combinations were excluded. This stringent selection process was used to define two homogeneous treatment groups and resulted in 19 patients fulfilling all the above-mentioned criteria (PTA  $n=8$ , PTAS  $n=11$ ).

### Procedures

Most of the interventional procedures were performed under general anesthesia ( $n=16$ , 84%). All procedures were performed on a Philips Allura Xper FD20/20 biplane angiography system (Philips Medical System, Best, the Netherlands) according to departmental protocol, with intraprocedural modification if required. Briefly, access was achieved through the right common femoral artery, where a 7F long-sheath system was placed. After conventional catheter-based angiography an interventional procedure was performed with the following two device systems: Neuro Elutax SV (Aachen Resonance, Luxembourg)—a CE-certified DEB specifically designed for neurointerventional procedures—with length 10–30 mm and diameters from 1.5 to 4 mm; and Wingspan stent system (Boston Scientific, Natick, USA) with Gateway PTA balloon catheter (Stryker Neurovascular, Fremont, California, USA)—a Food and Drug Administration approved angioplasty system specifically designed for the neurovascular arteries—as the standard and reference PTAS system.

For the Wingspan stent system the over-the-wire technique was used. The Neuro Elutax SV DEB is a monorail system

Submaximal angioplasty technique was performed for DEB deployment with a balloon inflation time of 30 s.<sup>15</sup>

The decision about which device to use was at the discretion of the neurointerventionalist in charge. Dual antiaggregation with aspirin and clopidogrel was initiated for at least 6 months in all patients treated with PTAS. In patients treated with pDEB Elutax, two patients received therapeutic anticoagulation owing to atrial fibrillation, three aspirin/clopidogrel, and three aspirin alone.

### Imaging

The degree of stenosis before and after intervention was determined according to NASCET criteria in cerebral digital subtraction angiography (DSA).<sup>16</sup> The follow-up stenoses were assessed according to the underlined follow-up imaging technique.

### Outcome measures

The primary outcome was the compound endpoint of recurrent stroke/TIA and/or restenosis. Restenosis was defined as radiological evidence of postinterventional stenosis of >50% measured by ultrasound, MRI, CT angiography or cerebral angiography during a median follow-up period of 4 months (range 1–9) for the Wingspan and 3 months (range 3–3.5) for the Elutax patients. Any focal neurological symptom related to the corresponding vascular territory occurring within the follow-up period was considered as recurrent stroke or a TIA. Secondary outcomes were stroke or any death within 30 days and good clinical outcome (modified Rankin Scale (mRS) score  $\leq 2$ ) at follow-up.

### Statistical analysis

Epidemiological, clinical and radiological data were acquired from the medical records.

All data were anonymized and reviewed by the authors. All statistical analyses were performed by using the STATA/IC 14.1 software (StataCorp LLC, Texas, USA). Study parameters were compared between the two patient groups using either a two-tailed *t*-test for continuous variables or the Wilcoxon rank sum test for categorical variables. Logistic regression analysis was performed. For all results, a *P* value <0.05 was considered statistically significant.

### RESULTS

A total of 19 patients (9 (47%) female) with 20 lesions (one tandem lesion) were eligible for this study. Eight patients (42%) were treated with a pDEB Elutax SV and; 11 patients (58%) with a Wingspan stent system. The median clinical follow-up was 9.5 months (IQR 4.5–27) for the Elutax patients and 10 months (IQR 6–58) for the PTAS patients, respectively ( $P=0.36$ ). There were no significant differences in the epidemiological and clinical baseline characteristics between the two groups (table 1). Median age was 68.5 years (IQR 52–76) for the Elutax patients and 67 years (IQR 59–73) for the Wingspan patients ( $P=0.86$ ). Both groups had similar distributions of vascular risk factors, such as hypertension, diabetes, dyslipidemia, smoking and atrial fibrillation (table 1). Median National Institute of Health Stroke Scale (NIHSS) score was 0 (IQR 0–4) for the Elutax patients and 2 (IQR 0–6) for the PTAS patients ( $P=0.28$ ). Seventy-five percent of the Elutax patients and 45% of the Wingspan patients had TIAs as initial presenting symptom ( $P=0.21$ ). Nearly all patients (90%) were on antiplatelet or anticoagulant therapy and received an anti-lipid agent before admission.

**Table 1** Demographic, clinical baseline and target lesion characteristics

| Characteristics  | Elutax (n=8)    | Wingspan (n=11) | P value |
|--|-----------------|-----------------|---------|
| Gender, female, n (%)                                    | 3 (38%)         | 6 (55%)         | 0.47    |
| Age (years), median (IQR)                                | 68.5 (52–76)    | 67 (59–73)      | 0.86    |
| Clinical follow-up (months), median (IQR)                | 9.5 (4.5–27)    | 10 (6–58)       | 0.36    |
| NIHSS score on admission, median (IQR)                   | 0 (0–4)         | 2 (0–6)         | 0.28    |
| Vascular risk factors                                    |                 |                 |         |
| Hypertension, n (%)                                      | 6 (75%)         | 8 (73%)         | 0.81    |
| Diabetes, n (%)  | 1 (13%)         | 4 (36%)         | 0.26    |
| Dyslipidemia, n (%)                                      | 3 (38%)         | 7 (64%)         | 0.28    |
| Coronary artery disease, n (%)                           | 4 (50%)         | 3 (27%)         | 0.53    |
| Smoking, n (%)   | 1 (13%)         | 2 (18%)         | 0.74    |
| Peripheral artery occlusive disease, n (%)               | 0 (0%)          | 1 (9%)          | 0.39    |
| Atrial fibrillation, n (%)                               | 1 (13%)         | 1 (9%)          | 0.82    |
| History of stroke, n (%)                                 | 3 (38%)         | 4 (36%)         | 0.96    |
| Medication on admission                                  |                 |                 |         |
| Aspirin, n (%)   | 3 (38%)         | 7 (64%)         | 0.27    |
| P2Y12 inhibitor, n (%)                                   | 1 (13%)         | 1 (9%)          | 0.82    |
| Dipyridamole, n (%)                                      | 0               | 1 (9%)          | 0.39    |
| Dual antiplatelet therapy, n (%)                         | 1 (13%)         | 1 (9%)          | 0.81    |
| Vitamin K antagonist, n (%)                              | 1 (13%)         | 0 (0%)          | 0.24    |
| NOAC, n (%)  | 1 (13%)         | 0 (0%)          | 0.24    |
| Anti-lipid agent, n (%)                                  | 6 (75%)         | 6 (55%)         | 0.51    |
| Severity of stenosis                                     |                 |                 |         |
| Degree of stenosis (%) before intervention, median (IQR) | 81% (72.5–92.5) | 80% (72–100)    | 0.87    |
| Degree of stenosis (%) after intervention, median (IQR)  | 37.5% (20–60)   | 10% (10–50)     | 0.23    |
| Localization of target lesions                           |                 |                 |         |
| Internal carotid artery, n (%)                           | 0 (0%)          | 1 (9%)          | 0.39    |
| Middle cerebral artery, n (%)                            | 3 (38%)         | 5 (45%)         | 0.74    |
| Vertebral artery, n (%)                                  | 3 (38%)         | 3 (27%)         | 0.64    |
| Basilar artery, n (%)                                    | 2 (25%)         | 2 (18%)         | 0.73    |

IQR, Interquartile range; mRS, modified Rankin Scale; NIHSS, National Institute of Health Stroke Scale; NOAC, novel oral anticoagulant.

The overall severity of stenosis in this study was 80% (median; IQR 75–95). The degree of stenosis was reduced from 81% (median; IQR 72.5–92.5) to 37.5% (median, IQR 20–60) in Elutax patients and from 80% (median, IQR 72–100) to 10% (median, IQR 10–50) in Wingspan patients ( $P=0.23$ ) (table 1). Localization of the target lesions was quite similar in both groups (table 1).

For the primary outcome (table 2), the compound endpoint of recurrent stroke/TIA and/or restenosis within the follow-up period of 9.5 months for the Elutax and 10 months for the Wingspan patients, respectively, was significantly lower for the Elutax patients ( $n=1$ , Wingspan  $n=7$ ,  $P=0.03$ ; logistic regression OR=0.08, CI 95%: 0.007 to 0.93,  $P=0.043$ ). No other correlation with demographic or baseline characteristics was found (data not shown).

No clinical re-events—defined as TIA or stroke in the vascular territory of the formerly treated stenosis within the follow-up

**Table 2** Clinical and technical outcome measures

| Outcome measures   | Elutax (n=8) | Wingspan (n=11) | P value |
|--|--------------|-----------------|---------|
| Good clinical outcome (mRS score $\leq 2$ ) at follow-up | 5 (63%)      | 9 (82%)         | 0.36    |
| mRS score on follow-up, median (IQR)                     | 1 (0–3)      | 1 (0–2)         | 0.95    |
| Stroke or death within 30 days, n (%)                    | 1 (13%)      | 0 (0%)          | 0.24    |
| Technical success*, n (%)                                | 5 (63%)      | 7 (64%)         | 0.96    |
| Transient ischemic attack, n (%)                         | 6 (75%)      | 5 (45%)         | 0.21    |
| Compound recurrence rate, n (%)                          | 1 (13%)      | 7 (64%)         | 0.03    |
| Clinical re-event, n (%)                                 | 0 (0%)       | 5 (45%)         | 0.03    |
| Restenosis, n (%)  | 1 (13%)      | 6 (55%)         | 0.068   |
| Specific complications, n (%)                            | 0 (0%)       | 2 (18%)         | 0.21    |
| Generic complications, n (%)                             | 0 (0%)       | 1 (9%)          | 0.39    |
| Technical failure, n (%)                                 | 1 (13%)      | 0 (0%)          | 0.24    |
| Number of devices used, median (IQR)                     | 1 (1–2)      | 3 (2–4)         | 0.003   |

\*Technical success; defined as <50% residual stenosis at the end of the intervention.

mRS, modified Rankin Scale.

period—were reported for Elutax patients, whereas 5 (36.45%) of Wingspan patients had new clinical symptoms in the corresponding vascular territory (TIA  $n=4$ , minor stroke  $n=1$ ). Of those patients, four out of five underwent conventional DSA; three of them needed immediate interventional procedure with angioplasty or intra-arterial thrombolysis. Median time to recurrent stroke/TIA was 3 months (IQR 1.5–4) after the intervention.

Restenosis rate—defined as any radiological evidence of stenosis degree >50%—tended to be higher in Wingspan treated patients ( $n=6$ ) than in the Elutax patients ( $n=1$ ,  $P=0.068$ ).

One death occurred owing to fatal vertebralbasilar stroke not related to the intervention (table 2).

Technical success—defined as <50% residual stenosis at the end of the interventional procedure—was achieved in 63% of the Elutax patients and 64% of the Wingspan patients ( $P=0.96$ ). Furthermore, significantly fewer different devices were needed for successful recanalization in the Elutax group which required one device (median, IQR 1–2) for each case compared with three devices (median, IQR 2–4) for each case in the Wingspan group ( $P=0.003$ ) (table 2).

There were no intraprocedural complications in 15/19 patients. Overall technical failure was 5% due to unsuccessful deployment of a pDEB because of difficult local anatomical conditions in an Elutax patient (Elutax: 13%; Wingspan: 0%,  $P=0.24$ ). Generic complications were reported for only one Wingspan patients (9%) due to a groin hematoma at puncture site, which had to be surgically evacuated. Specific complications were seen in two Wingspan-treated patients: one had an intraprocedural in-stent thrombosis and the other had a consecutive hyperperfusion syndrome with transient neurological deterioration. No other procedure-related neurological complications, such as vessel perforation, dissections, subarachnoid hemorrhage, intracranial hemorrhage, or ischemic events, were found (table 2).

Finally, there were no differences between the two groups in good clinical outcome (modified Rankin Scale (mRS) score  $\leq 2$ , table 2), with a median mRS of 1 (IQR 0–3) for the Elutax patients, and a median mRS of 1 (IQR 0–2) for the Wingspan patients, respectively ( $P=0.95$ ).

## DISCUSSION

To our knowledge, this is the first cohort study reporting a pDEB specifically dedicated to neurovascular application (Elutax SV) and the Wingspan stent system in patients with intracranial symptomatic high-grade atherosclerotic arterial stenosis. During a median follow-up period of 9.5 months (Elutax) and 10 months (Wingspan), recurrent stroke/TIA was significantly lower in Elutax-treated patients than in the Wingspan group. Likewise, restenosis tended to be lower in Elutax patients. There was no significant difference in complication rate and outcome at follow-up.

ICAD is a common cause of ischemic stroke and patients with high-grade intracranial stenosis (70–99%), in particular, are at high risk of developing an ischemic event in the vascular territory of the stenosis.<sup>17</sup> These lesions may be amenable to intracranial angioplasty, but several concerns have been raised about this technique.

Evidence derived from cardiology has proved the efficacy and safety of DEB in coronary angioplasty. Since the first RCT of pDEB in coronary angioplasty for in-stent thrombosis, which found a significantly lower restenosis rate in the pDEB group (5% vs 43%,  $P=0.002$ ),<sup>8</sup> the benefit of pDEB has become evident and the superiority of pDEB over conventional balloon catheters has also been proved in long-term follow-up studies.<sup>18,19</sup>

Conversely, the role of DEB, and especially pDEB, in the neurovascular setting is still unclear. Since the publication of the SAMMPRIS trial in 2011,<sup>2</sup> best medical care is regarded as the preferred treatment for ICAD because of the high periprocedural complication rate of 14.7%. This rate was considerably higher than in previously published data—for example, data from the European INTRASTENT multicentric registry, which had an intrahospital event rate of 7%.<sup>20</sup> Furthermore, a high incidence of recurrent stenosis of up to 31% appears to be a major problem with intracranial stenting, despite growing experience in procedural feasibility, safety, and durability of revascularization.<sup>21,22</sup> These restenoses may result in up to 39% of patients having a TIA or stroke.<sup>23</sup> Therefore, enthusiasm for using intracranial stenting has declined over the past years.

A review of intracranial angioplasty showed a relatively low incidence of 30-day major complications of  $\leq 6\%$ , but the rate of symptomatic and angiographic restenosis after 6 months was still 5–30%.<sup>24</sup> By using drug-eluted devices for the ICAD treatment, the rate of restenosis and clinical re-events may be reduced, as was shown in early studies.<sup>11–13</sup> However, their efficacy has not yet been totally confirmed in ICAD. So far, a study of a large cohort of 95 patients with ICAD treated with a sirolimus-coated coronary DES system (Coroflex Plaease Stent) has reported promising results, with a low restenosis rate of 3.9% and a low periprocedural complication rate of 0.9%.<sup>10</sup> In our study, a paclitaxel-coated balloon specifically designed for neurovascular application was used. Restenosis is mainly caused by intimal hyperplasia. Paclitaxel is a highly lipophilic anticancer drug and has an antiproliferative effect. By inhibiting the proliferation of smooth muscle cells, paclitaxel reduces intimal hyperplasia.<sup>25</sup> Thus, paclitaxel has been proved to be a potent agent to prevent restenosis.<sup>26</sup>

Preliminary good results with pDEB have been shown in different small case series for the treatment of restenosis in internal carotid artery stenosis.<sup>27,28</sup> But, experience of pDEB treatment in ICAD is limited to only one case series of 51 patients with ICAD, demonstrating a significantly lower restenosis rate than with a conventional stent system (9% vs 50%) during a mean follow-up of 6.5 and 7.5 months, respectively.<sup>29</sup> Our results support these findings that pDEB-treated patients have

less restenosis and fewer cerebrovascular re-events than patients treated with conventional bare-metal stent and uncoated balloon catheters. The relatively high rate of restenosis of 36% in our Wingspan group is not surprising and is in-line with previous reports of up to 34%.<sup>24</sup>

Interestingly, despite the submaximal angioplasty technique with greater residual stenosis, the restenosis rate remained low. This is of special interest, because there are concerns about the effective interaction of the drug-coated surface of the DEB and the targeted vessel walls when the submaximal angioplasty technique is applied.<sup>24</sup>

Furthermore, the technical success rate was lower for both groups (Elutax vs Wingspan) with 63% and 64%, respectively, compared with previous studies with success rates of 70–100%.<sup>22</sup> Our results might be related to the submaximal angioplasty technique and low patient number. Despite the small number of patients, the technical failure rate was comparably low, with only one unsuccessful pDEB deployment in an anatomically difficult lesion. The deployment failure might be due to the greater rigidity and stiffness of the balloon because of the coated surface. Subsequent technical advances in catheter design may overcome this problem in the future, and may lead to softer and more flexible balloons.

No other severe incidents, such as vessel perforation, dissections, subarachnoid hemorrhage, or intracranial hemorrhage, occurred either in the short or long term. Therefore, the overall safety for the pDEB patients was good and lower as reported for PTAS patients in a recent meta-analysis.<sup>30</sup> Thus, a large sample size is needed, to definitively confirm the success rate and safety profile of the Neuro Elutax SV.

Finally, clinical outcome was favorable, with a median mRS score of 1 in both groups. However, there are differences in the initial NIHSS and clinical presentation in the two groups with insignificant, but a higher proportion of TIAs in the pDEB patients than in the PTAS patients, which might have biased the outcome for each group.

Major limitations are the retrospective design, lack of randomization and the small number of eligible patients because following the SAMMPRIS trial, patients with ICAD are primarily treated with platelet inhibitors without mechanical recanalization. Furthermore, the follow-up was relatively short. Because of the retrospective design, routine follow-up DSA to describe the treated stenosis at 90 days is not a common procedure at our institution, thus follow-up imaging is always based on ultrasound or other non-invasive imaging techniques. In addition, these data are obtained from only one experienced high-volume single center and thus may not be generally applicable.

Finally, our observations suggest that drug-eluting balloon angioplasty might be a valid option for patients with ICAD with intractable disease despite best medical care, because the technical advances of newer DEB generations has led to a lower complication rate with an overall good clinical and radiological outcome. Thus, large-scale, prospective studies are needed.

## CONCLUSION

The pDEB Neuro Elutax SV may be a promising alternative treatment for highly selected patients with ICAD, showing a lower recurrence rate than with the PTAS Gateway/Wingspan with a similar safety profile and technical success rate. Despite a significant difference in the recurrence rate, conclusions have to be reached with caution owing to the limitations of this study. Further studies will be needed to clearly elucidate the role of pDEB in the management of symptomatic intracranial high-grade stenosis.

**Contributors** PG made substantial contributions to the conception and design of the work, and to acquisition, analysis, and interpretation of data for the work; CG-E, JB, TK made substantial contributions to the conception and design of the work, and revised it critically for important intellectual content; MH, JA, MD, KN revised the paper critically for important intellectual content; LR conceived and designed the work, revising it critically for important intellectual content, and gave final approval of the version to be published.

**Funding** The authors have not declared a specific grant for this research from any funding agency in the public, commercial, or not-for-profit sectors.

**Competing interests** None declared.

**Patient consent** Not required.

**Ethics approval** EKNZ.

**Provenance and peer review** Not commissioned; externally peer reviewed.

© Article author(s) (or their employer(s) unless otherwise stated in the text of the article) 2018. All rights reserved. No commercial use is permitted unless otherwise expressly granted.

## REFERENCES

- Vellimana AK, Ford AL, Lee JM, *et al.* Symptomatic intracranial arterial disease: incidence, natural history, diagnosis, and management. *Neurosurg Focus* 2011;30:E14.
- Chimowitz MI, Lynn MJ, Derdeyn CP, *et al.* Stenting versus aggressive medical therapy for intracranial arterial stenosis. *N Engl J Med* 2011;365:993–1003.
- Fiorella D, Levy EI, Turk AS, *et al.* US multicenter experience with the wingspan stent system for the treatment of intracranial atheromatous disease: periprocedural results. *Stroke* 2007;38:881–7.
- SSYLIA Study Investigators. Stenting of Symptomatic Atherosclerotic Lesions in the Vertebral or Intracranial Arteries (SSYLIA): study results. *Stroke* 2004;35:1388–92.
- Kernan WN, Ovbiagele B, Black HR, *et al.* Guidelines for the prevention of stroke in patients with stroke and transient ischemic attack: a guideline for healthcare professionals from the American Heart Association/American Stroke Association. *Stroke* 2014;45:2160–236.
- Farooq MU, Al-Ali F, Min J, *et al.* Reviving intracranial angioplasty and stenting "SAMMPRIS and beyond". *Front Neurol* 2014;5:101.
- Gao P, Zhao Z, Wang D, *et al.* China Angioplasty and Stenting for Symptomatic Intracranial Severe Stenosis (CASSISS): a new, prospective, multicenter, randomized controlled trial in China. *Interv Neuroradiol* 2015;21:196–204.
- Cui XP, Lin M, Mu JS, *et al.* Angioplasty and stenting for patients with symptomatic intracranial atherosclerosis: study protocol of a randomised controlled trial *BMJ Open* 2016;6:e012175.
- Scheller B, Hehrlein C, Bocksch W, *et al.* Treatment of coronary in-stent restenosis with a paclitaxel-coated balloon catheter. *N Engl J Med* 2006;355:2113–24.
- Vajda Z, Aguilar M, Göhringer T, *et al.* Treatment of intracranial atherosclerotic disease with a balloon-expandable paclitaxel eluting stent. *Clin Neuroradiol* 2012;22:227–33.
- Abou-Chebl A, Bashir Q, Yadav JS. Drug-eluting stents for the treatment of intracranial atherosclerosis. *Stroke* 2005;36:e165–8.
- Qureshi AI, Kirmani JF, Hussein HM, *et al.* Early and intermediate-term outcomes with drug-eluting stents in high-risk patients with symptomatic intracranial stenosis. *Neurosurgery* 2006;59:1044–51.
- Miao ZR, Feng L, Li S, *et al.* Treatment of symptomatic middle cerebral artery stenosis with balloon-mounted stents: long-term follow-up at a single center. *Neurosurgery* 2009;64:79–84.
- Abdihallim MM, Hassan AE, Qureshi AI. Off-label use of drugs and devices in the neuroendovascular suite. *AJNR Am J Neuroradiol* 2013;34:2054–63.
- Levy EI, Howington JU, Eng JA, *et al.* Submaximal angioplasty and staged stenting for severe posterior circulation intracranial stenosis: a technique in evolution. *Neurocrit Care* 2005;2:189–97.
- Barnett HJ, Taylor DW, Eliasziw M, *et al.* Benefit of carotid endarterectomy in patients with symptomatic moderate or severe stenosis. North American Symptomatic Carotid Endarterectomy Trial Collaborators. *N Engl J Med* 1998;339:1415–25.
- Chimowitz MI, Lynn MJ, Howlett-Smith H, *et al.* Comparison of warfarin and aspirin for symptomatic intracranial arterial stenosis. *N Engl J Med* 2005;352:1305–16.
- Kufner S, Cassese S, Valeskini M, *et al.* Long-term efficacy and safety of paclitaxel-eluting balloon for the treatment of drug-eluting stent restenosis: 3-year results of a randomized controlled trial. *JACC Cardiovasc Interv* 2015;8:877–84.
- Scheller B, Clever YP, Kelsch B, *et al.* Long-term follow-up after treatment of coronary in-stent restenosis with a paclitaxel-coated balloon catheter. *JACC Cardiovasc Interv* 2012;5:323–30.
- Kurre W, Berkefeld J, Brassel F, *et al.* In-hospital complication rates after stent treatment of 388 symptomatic intracranial stenoses: results from the INTRAStent multicentric registry. *Stroke* 2010;41:494–8.
- Vajda Z, Schmid E, Güthe T, *et al.* The modified Bore method for the endovascular treatment of intracranial atherosclerotic arterial stenoses using the Enterprise stent. *Neurosurgery* 2012;70:91–101.
- Gröschel K, Schnaidigel S, Pilgram SM, *et al.* A systematic review on outcome after stenting for intracranial atherosclerosis. *Stroke* 2009;40:e340–7.
- Fields JD, Liu KC, Barnwell SL, *et al.* Indications and applications of arterial stents for stroke prevention in atherosclerotic intracranial stenosis. *Curr Cardiol Rep* 2010;12:20–8.
- McTaggart RA, Marks MP. The case for angioplasty in patients with symptomatic intracranial atherosclerosis. *Front Neurol* 2014;5:36.
- De Labriolle A, Pakala R, Bonello L, *et al.* Paclitaxel-eluting balloon: from bench to bed. *Catheter Cardiovasc Interv* 2009;73:643–52.
- Scheller B, Speck U, Abramjuk C, *et al.* Paclitaxel balloon coating: a novel method for prevention and therapy of restenosis. *Circulation* 2004;110:810–4.
- Liistro F, Porto I, Grotti S, *et al.* Drug-eluting balloon angioplasty for carotid in-stent restenosis. *J Endovasc Ther* 2012;19:729–33.
- Montorsi P, Galli S, Ravagnani PM, *et al.* Drug-eluting balloon for treatment of in-stent restenosis after carotid artery stenting: preliminary report. *J Endovasc Ther* 2012;19:734–42.
- Vajda Z, Güthe T, Perez MA, *et al.* Neurovascular in-stent stenoses: treatment with conventional and drug-eluting balloons. *AJNR Am J Neuroradiol* 2011;32:1942–7.
- Tsigoulis G, Katsanos AH, Magoufis G, *et al.* Percutaneous transluminal angioplasty and stenting for symptomatic intracranial arterial stenosis: a systematic review and meta-analysis. *Ther Adv Neurol Disord* 2016;9:351–8.





## Clinical Research

# Angioplasty Using Drug-Coated Balloons in Ostial Vertebral Artery Stenosis

Philipp Gruber,<sup>1,2</sup> Jatta Berberat,<sup>1</sup> Timo Kahles,<sup>2</sup> Javier Anon,<sup>1</sup> Michael Diepers,<sup>1</sup> Krassen Nedeltchev,<sup>2,3</sup> and Luca Remonda,<sup>1,3</sup> Aarau and Bern, Switzerland

**Background:** Ostial vertebral artery stenosis (OVAS) is a relevant cause of acute ischemic posterior circulation stroke. Percutaneous trans-luminal angioplasty (PTA) might offer a promising treatment modality, but restenosis rate is high. So far, little is known about recanalization using drug-coated balloons (DCB) in OVAS. We aimed to show feasibility and safety of DCB-PTA in OVAS.

**Methods:** Retrospective, monocenter case series of 12 patients with ostial vertebral artery stenosis ( $\geq 50\%$ ) treated with PTA using a drug-coated balloon.

**Results:** Median age was 69.5 years (IQR 57–78.5) with a female rate of 41%. Patients were treated either with a SeQuent Please NEO or Neuro Elutax SV DEB. Median preinterventional stenosis degree was 75% (IQR 70–85) with a median lesion length of 4.5 mm (IQR 4–7.5). Median postinterventional stenosis degree was 40% (IQR 27–50). All treated vessels remained patent. No major complications such as dissection, vessel perforation, hemorrhage, or ischemic events occurred. Moreover, we did not detect any restenosis during a median follow-up period of 6.1 months. The clinical outcome was excellent with median mRS scale of 0 (IQR 0–1).

**Conclusions:** PTA using drug-coated balloons is feasible and safe in patients with ostial vertebral artery stenosis.

## INTRODUCTION

Approximately 20–25% all of ischemic strokes occur in the posterior circulation, and 10–20% of the patients with ostial vertebral artery stenosis

(OVAS) will suffer from a stroke.<sup>1,2</sup> Furthermore, patients with a vertebrobasilar transient ischemic attack (TIA) due to OVAS ( $\geq 50\%$ ) have a 5-year risk of stroke recurrence of 30%.<sup>3</sup> In addition, the risk of stroke or death is six times higher in OVAS patients than in patients without OVAS.<sup>4</sup>

Nevertheless, there is an ongoing debate on the treatment modalities for OVAS patients whether patients benefit from endovascular or from best-medical treatment alone since the VIST, VAST, and CAVATS trial.<sup>5–7</sup> Today, best medical treatment using antiplatelet agents is considered first-line treatment of OVAS.<sup>8</sup> However, endovascular OVAS treatment might be considered especially in patients with hemodynamic vertebrobasilar insufficiency, bilateral  $>70\%$  vertebral artery stenosis (VAS) and in patients with unilateral VAS with contralateral hypoplastic or occluded vessels.<sup>9</sup> Initial good clinical results and high success rates have been reported for percutaneous angioplasty with or without stenting. However, the restenosis rate was reported as high as 10–67%.<sup>10,11</sup>

*Funding Statement:* This research received no specific grant from any funding agency in the public, commercial, or not-for-profit sectors.

*Competing Interests Statement:* No conflicts of interest have to be reported.

*Data Sharing:* N/A.

<sup>1</sup>Department of Neuroradiology, Cantonal Hospital Aarau, Aarau, Switzerland.

<sup>2</sup>Department of Neurology, Cantonal Hospital Aarau, Aarau, Switzerland.

<sup>3</sup>University of Bern, Bern, Switzerland.

Correspondence to: Philipp Gruber, MD, MSc, Department of Neuro-radiology, Cantonal Hospital Aarau, Tellstrasse, CH-5001, Aarau, Switzerland; E-mail: philipp.gruber@ksa.ch

Ann Vasc Surg 2019; ■ : 1–6  
<https://doi.org/10.1016/j.avsg.2019.10.043>

© 2019 Elsevier Inc. All rights reserved.

Manuscript received: August 7, 2019; manuscript accepted: October 1, 2019; published online: ■ ■ ■



During the last decade, drug-eluting stents (DES) and drug-coated balloons (DCB) have been established in the field of interventional cardiology with convincing short- and long-term results.<sup>12</sup> In line with these observations, several case series as well as cohort studies in OVAS patients treated with DES have been published and demonstrated feasibility and safety with high technical success rates of 98.8% and low morbidity.<sup>8</sup> DES in patients with high-grade OVAS appear to have lower restenosis rates compared to the previously used bare-metal stents (BMS).<sup>13,14</sup> Data on treatment of high-grade OVAS with DCB is scarce.<sup>15</sup> DCB offers the opportunity to prevent restenosis through a drug-coated matrix that releases antiproliferative drugs inhibiting neointimal hyperplasia<sup>16</sup> on one hand and omits the permanent deployment of extraneous material on the other hand.

In this case series, we assessed feasibility and safety of DCB-PTA in patients with OVAS ( $\geq 50\%$ ) using Neuro Elutax SV (Aachen Resonance, Aachen, Germany) and SeQuent Please NEO (B. Braun Melsungen, Germany).

## METHODS

### Patient Selection

In this retrospective monocenter case series, we screened our stroke database for patients ( $\geq 18$  years) with OVAS ( $\geq 50\%$ ) treated with DCB-PTA within the last 3 years. The OVAS degree was based on a multimodality imaging approach (CTA, MRA, and/or US) that has to be confirmed by conventional angiography.

We identified 12 patients with either symptomatic OVAS ( $n = 10$ ) or treatment of OVAS in order to improve the collateral situation in two patients suffering from complex occlusive vasculopathies with additional high-grade stenosis of the internal carotid arteries, as well as stenosis or occlusion of the contralateral vertebral artery. Thus, our indications were high-risk patients with recurrent TIAs or manifest strokes in the posterior circulations and additional OVAS, as well as patients with complex occlusive, supra-aortic vasculopathies with concomitant high-grade OVAS and with insufficient collateral circuits.

The local ethics committee (Ethikkommission Nordwest und Zentralschweiz, EKNZ, 2018-01,204) approved the study.

### Procedure

Preinterventionally, patients received either a dual antiplatelet therapy (DAPT) with aspirin 100 mg

and clopidogrel 75 mg ( $n = 9$ ; 75%) or in case of concomitant atrial fibrillation anticoagulation with rivaroxaban 15 mg and antiplatelet therapy with clopidogrel 75 mg ( $n = 3$ ; 25%) according to the PIONEER-AF trial.<sup>17</sup> Prior to the intervention, an additional heparin bolus (range 2,500–5,000 I.E.) adjusted for body weight was administered according to activating clotting time (ACT) blood test. Most of the procedures were performed under general anesthesia ( $n = 9$ ; 75%).

All endovascular procedures were performed on a biplane angiography system (Allura Xper, Philips, the Netherlands). The tip of 6F guiding catheter was placed via a 7F femoral access sheath into the proximal part of the subclavian artery. Under roadmap guidance, a flexible 0.0014-inch microwire (Synchro2, Stryker Neurovascular, USA) was directed across the lesion. The tip of the microwire was always placed into the distal part of the extracranial vertebral artery. By monorail technique, a properly sized Neuro Elutax SV or a SeQuent Please NEO DCB was placed across the lesion covering at least the plaque lesion length. Then, DCBs were gently inflated to subnominal pressure (first run with first device: median 9 bar, interquartile range IQR 6–10 bar) according to submaximal angioplasty technique as described elsewhere and kept inflated for 30–60 sec.<sup>18</sup> In all cases, a final postprocedural angiography was performed to document the final result as well to exclude vessel dissection, distal embolization, or vessel perforation. Within 24 hours after the procedure, patients were controlled for immediate restenosis with ultrasound. These results served also as a baseline examination for follow-up imaging.

Postprocedurally, one patient initially on DAPT was newly diagnosed with atrial fibrillation and was switched to rivaroxaban 15 mg and clopidogrel 75 mg/d. In addition, another four patients initially on DAPT were switched to aspirin only directly after the intervention. Furthermore, all patients were under lipid-lowering medication, and vascular risk factors were controlled and treated if necessary.

### Outcome Measurements

We measured postprocedural angiographic stenosis degree according to the VOTE method criteria,<sup>19</sup> as well as the postprocedural short-term (within 24 hours) and long-term ultrasonographic stenosis degree according to the nomogram of Ranke et al.<sup>20</sup> Additionally, all periprocedural complications as well as clinical follow-up (mRS) were assessed.

**Table I.** Cohort characteristics and outcome parameters of the study

|  | <i>N</i> = 12      |
|--|--------------------|
| <b>Clinical characteristics</b>                                      |                    |
| Age in years (yrs), median (IQR)                                     | 69.5 yrs (57–78.5) |
| Sex (female), <i>n</i> (%)   | 5 (41)             |
| Hypertension, <i>n</i> (%)   | 12 (100)           |
| Dyslipidemia, <i>n</i> (%)   | 10 (83)            |
| Diabetes mellitus, <i>n</i> (%)                                      | 3 (25)             |
| Heart disease, <i>n</i> (%)  | 7 (58)             |
| Atrial fibrillation, <i>n</i> (%)                                    | 4 (33.3)           |
| History of nicotine abuse, <i>n</i> (%)                              | 8 (67)             |
| NIHSS, median (IQR)  | 0 (0–0)            |
| <b>Lesion Characteristics</b>  |                    |
| Lesion side (left), <i>n</i> (%)                                     | 12 (100)           |
| Preinterventional stenosis degree VOTE in percentage, median (IQR)   | 75% (70–85)        |
| Lesion length in mm, median (IQR)                                    | 4.5 (4–7.5)        |
| Most common clinical symptom: vertigo/dizziness                      | 7 (58%)            |
| <b>Contralateral vertebral artery (VA)</b>                           |                    |
| Hypoplastic V4-segment of the VA                                     | 2 (17%)            |
| Occlusion/Pseudo-occlusion of the VA                                 | 2 (17%)            |
| High-grade stenosis ( $\geq 70$ )                                    | 2 (17%)            |
| Moderate stenosis ( $\leq 50$ %)                                     | 2 (17%)            |
| <b>Procedure Characteristics</b>                                     |                    |
| General anesthesia, <i>n</i> (%)                                     | 9 (75)             |
| Neuro Elutax-SV as first DCB, <i>n</i> (%)                           | 6 (50)             |
| SeQuent Please NEO as first DCB, <i>n</i> (%)                        | 6 (50)             |
| Second larger-size DCB use, <i>n</i> (%)                             | 4 (44)             |
| Change to another DCB, <i>n</i> (%)                                  | 1 (11)             |
| <b>Outcome Measures</b>  |                    |
| Modified ranking scale score at follow-up, median (IQR)              | 0 (0–1)            |
| Postinterventional stenosis degree VOTE in percentage – median (IQR) | 40% (27–50)        |
| Mean follow-up period in months                                      | 6.1                |
| Recurrent clinical ischemic event, <i>n</i>                          | 0                  |
| Restenosis rate at follow-up, <i>n</i>                               | 0                  |
| Overall major periprocedural complications, <i>n</i>                 | 0                  |
| Dissection, <i>n</i>   | 0                  |
| Vessel perforation, <i>n</i>   | 0                  |
| Hemorrhage, <i>n</i>   | 0                  |
| Distal ischemic event, <i>n</i>                                      | 0                  |
| Mortality, <i>n</i>  | 0                  |

DCB, drug coated balloon; IQR, interquartile range; NIHSS, National Institute of Health Stroke Scale; no., number; VA, vertebral artery; VOTE, vertebral origin treatment with endovascular therapy method; yrs, years.

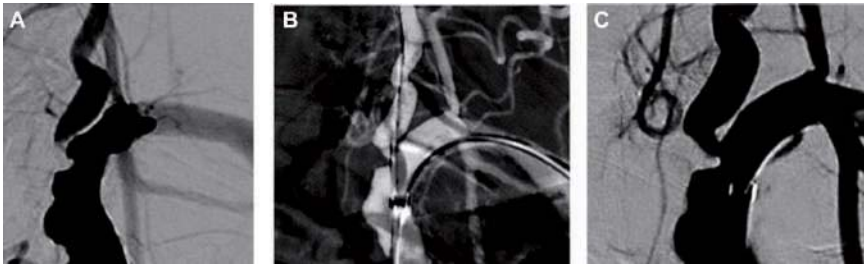
## RESULTS

In this case series, median age was 69.5 years (IQR 66–76). There was a female rate of 41%. Most prevalent vascular risk factors were hypertension ( $n = 12$ ; 100%), followed by dyslipidemia ( $n = 10$ , 83%) (Table I). Eleven patients were also under previous antiplatelet therapy (APT) ( $n = 7$ ), dual antiplatelet therapy (DAPT) ( $n = 2$ ), or anticoagulation ( $n = 1$ ) as well as anticoagulation and APT ( $n = 1$ ). Prior to the intervention, 11 patients were already under Statin therapy. All culprit lesions were located on the left side. In 33% ( $n = 4$ ) of the

patients, additional stenoses on the same side were found, of whom one patient with a concomitant high-grade V2/V3 segment stenosis of VA was additionally treated with PTA-DCB. In 67% ( $n = 8$ ) of the patients, a moderate-to-severe contralateral vertebral artery lesion was found such as occlusion, bilateral OVAS, or hypoplastic vertebral arteries (Table I).

Preinterventional stenosis degree according to the VOTE method was 75% (IQR 70–85).

Neuro Elutax SV DCB and Sequent Please NEO DCB were equally used as first-line in three cases. In four cases, the initially used DCBs were changed



**Fig. 1.** Central illustration: Illustrative case of DCB use in ostial vertebral artery stenosis. Patient with known extensive atherosclerotic arteriopathy of supra-aortic arteries. **(A)** Preprocedural angiogram of a high-grade, excentric OVAS of the left vertebral artery. **(B)** Intraprocedural inflated angioplasty balloon (SeQuent Please

NEO). four-time angioplasty with two times 2 mm  $\times$  10 mm SeQuent-Please NEO and two times with a 3 mm  $\times$  10 mm SeQuent Please NEO. **(C)** Postprocedural angiogram with residual stenosis (50%) with good restoration of antegrade flow.

to larger sized DCBs of the same manufacturer. One patient required a switch from Neuro Elutax SV DCBs (attempt with two different sizes) to SeQuent Please NEO DCB). Final deployment of DCBs was technically successful in all cases.

Median postprocedural stenosis degree was 40% (IQR 27–50) and ultrasonographically the treated vessel remained open within the first 24 hours. There was no correlation between the initial lesion characteristics and outcome. The clinical outcome was excellent with median modified Ranking Scale (mRS) Score at follow-up of 0 (IQR 0–1).

We did not observe any major complication such as vessel dissection, vessel perforation, ischemic or hemorrhagic intracranial events.

During a mean follow-up period of 6.1 months, postprocedural ultrasound findings showed in 7 (58%) patients normalized flow profile and in 5 (42%) patients residual stenosis. During this follow-up period, no clinical recurrent strokes occurred.

## DISCUSSION

Our findings showed that OVAS treatment with DCB in appropriately selected patients is feasible, safe, and revealed sustained short-outcome results (Fig. 1). These findings are in line with a previous case report of DCB in OVAS.<sup>15</sup>

Vertebral artery stenosis is the second most common stenosis in the extracranial vasculature after carotid artery stenosis and might have deleterious effect if it becomes symptomatic. There is still the

question, which patients will benefit most from endovascular therapy.

## Anatomical Considerations

Most of our patients had also pathoanatomical changes of the contralateral side and nearby all of these lesions—comprising high-grade OVAS, hypoplastic VA, or occluded VA—together with the culprit OVAS might also lead to vertebro-basilar insufficiency. Thus, these OVAS should be endovascularly treated as recommended by others.<sup>9,21</sup> Interestingly, all culprit lesions were located on the left side. As often reported in anatomical studies, the left VA diameter is commonly the larger one of both VAs.<sup>22,23</sup> This might have some hemodynamic implications in atherosclerotic VAs, because the left VA might be the dominant artery in this constellation. And, as soon as this VA will be severely affected by atherosclerosis, vertebrobasilar insufficiency will occur.

## Technical Considerations

Since endovascular mechanical vessel treatment leads to vessel wall injuries, restenosis after endovascular OVAS treatment remains a medical challenge and was reported to be as high as 25–30% in stenting.<sup>24</sup> The underlying pathobiological mechanism is smooth muscle cell proliferation that causes neointimal hyperplasia and that is considered to be responsible for restenosis. Thus, DES/DCB use intends to deliver antiproliferative and immunomodulatory drugs that will prevent neointimal hyperplasia.<sup>12</sup> So far, DES has shown to be feasible,

safe, and effective<sup>25–27</sup> as well as superior over bare metal stents regarding restenosis rate as reported with 4.5% (DES) versus 19.1% (BMS) and in a meta-analysis of 442 OVAS patients with 4.7% (DES) and 11.6% (BMS),<sup>14,28</sup> since its first description in 2004.<sup>29</sup> Nevertheless, stenting has some shortcomings, which might be challenged by the use of DCB<sup>30</sup>. First, DCBs are more flexible compared to BMS/DES that may be of importance regarding the tortuous vessel anatomy mostly found in OVAS patients. Second, compared to DES (strut design), DCB covers the whole stenosis surface with a homogenous drug delivery and thus might better inhibit neointimal hyperplasia. Third, there is no residual foreign body left in the treated vessels and might enhance positive vessel remodeling. Fourth, multiple balloon use in the same lesion is possible. Fifth, since there is continuous mobility of the subclavian artery and tortuous anatomy of OVAS, restenosis could also be promoted by stent fracture or kinking due to mechanical stress, which could be detected up to 21.6% of cases,<sup>13,31</sup> a finding that cannot occur in DCB-PTA.

In addition, just recently, promising results have been shown for DCB treatment in symptomatic intracranial atherosclerotic disease (ICAD).<sup>32,33</sup> These results might even encourage the use of DCB also in the extracranial vasculature.

We observed no periprocedural complications. This finding is similar to that reported from different endovascular vertebral artery stenting studies with 0–5%,<sup>8,10</sup> supporting that endovascular treatment in OVAS is a relatively safe procedure. In addition, we did not use any distal protection device to prevent embolic events, as it has been described in some studies for OVAS stenting.<sup>21</sup> Additional devices in this mostly tortuous vessel anatomy of vertebral artery leads to additional complexity and might lead to higher complication rates.

Our technical success was also high, which is consistent with previous studies.<sup>8,14</sup> We had also no recurrent event, which has to be taken with caution because of low number and short follow-up.

There is a low risk of delayed endothelialization and incomplete neointimal healing in DCB compared to DES. Thus, there is no late and very late thrombosis risk. Therefore, DCB patients might not need a prolonged duration of DAPT compared to DES patients in whom duration of DAPT is recommended up to 3–6 months.<sup>34</sup> In cardiac DCB patients, the duration of DAPT for 1 month was suggested to be sufficient.<sup>35</sup> Furthermore, in DCB studies using shorter durations of DAPT (1–3 months), there was no significant increase of major adverse cardiac events compared to longer DAPT durations observed.<sup>12</sup> Of

note, this might also be an advantage for complex cardiovascular patients who need additional anticoagulation such as in patients with AF. Thus, in our cohort, 33.3% patients ( $n = 3$ ) were under novel oral anticoagulant (rivaroxaban) combined with clopidogrel without any bleeding complications. The other nine patients received DAPT during the endovascular procedure, and clopidogrel was discontinued immediately after the intervention in four patients, after 2 months in three patients.

### Limitations

Limitations are the small sample sizes and the lack of randomization, as well as the relatively short follow-up as it is known that in DCS, restenosis could appear even 42 months after implantation. Nevertheless, this case series might serve as a pilot study to encourage larger DCB-PTA studies in OVAS.

### CONCLUSION

This study demonstrated the feasibility and safety drug-coated balloon PTA in ostial vertebral artery stenosis. Drug-coated balloons might be considered as a novel treatment option in patients with ostial vertebral artery stenosis.

### REFERENCES

1. Savitz SI, Caplan LR. Vertebrobasilar disease. *N Engl J Med* 2005;352:2618–26.
2. Qureshi AI, Babar S, Saeed O, et al. Vertebral artery occlusive disease: data from the angiographically confirmed vertebral artery disease registry. *J Stroke Cerebrovasc Dis* 2018;27:3294–300.
3. Jenkins JS, Patel SN, White CJ, et al. Endovascular stenting for vertebral artery stenosis. *J Am Coll Cardiol* 2010;55:538–42.
4. Thompson MC, Issa MA, Lazzaro MA, et al. The natural history of vertebral artery origin stenosis. *J Stroke Cerebrovasc Dis* 2014;23:e1–4.
5. Markus HS, Larsson SC, Kuker W, et al. Stenting for symptomatic vertebral artery stenosis: the vertebral artery ischaemia stenting trial. *Neurology* 2017;89:1229–36.
6. Compter A, van der Worp HB, Schonewille WJ, et al. Stenting versus medical treatment in patients with symptomatic vertebral artery stenosis: a randomised open-label phase 2 trial. *Lancet Neurol* 2015;14:606–14.
7. Coward LJ, McCabe DJ, Ederle J, et al. Long-term outcome after angioplasty and stenting for symptomatic vertebral artery stenosis compared with medical treatment in the Carotid and Vertebral Artery Transluminal Angioplasty Study (CAVATAS): a randomized trial. *Stroke* 2007;38:1526–30.
8. Borhani Haghighi A, Edgell RC, Cruz-Flores S, et al. Vertebral artery origin stenosis and its treatment. *J Stroke Cerebrovasc Dis* 2011;20:369–76.
9. Jenkins JS, Stewart M. Endovascular treatment of vertebral artery stenosis. *Prog Cardiovasc Dis* 2017;59:619–25.

10. Chen X, Huang Q, Hong B, et al. Drug-eluting stent for the treatment of symptomatic vertebral origin stenosis: long-term results. *J Clin Neurosci* 2011;18:47–51.
11. Investigators SS. Stenting of Symptomatic Atherosclerotic Lesions in the Vertebral or Intracranial Arteries (SSYLVA): study results. *Stroke* 2004;35:1388–92.
12. Jackson D, Tong D, Layland J. A review of the coronary applications of the drug coated balloon. *Int J Cardiol* 2017;226:77–86.
13. Tank VH, Ghosh R, Gupta V, et al. Drug eluting stents versus bare metal stents for the treatment of extracranial vertebral artery disease: a meta-analysis. *J Neurointerv Surg* 2016;8:770–4.
14. Langwieser N, Buyer D, Schuster T, et al. Bare metal vs. drug-eluting stents for extracranial vertebral artery disease: a meta-analysis of nonrandomized comparative studies. *J Endovasc Ther* 2014;21:683–92.
15. Wang Y, Ma Y, Gao P, et al. First report of drug-coated balloon angioplasty for vertebral artery origin stenosis. *JACC Cardiovasc Interv* 2018;11:500–2.
16. Kempin W, Kaule S, Reske T, et al. In vitro evaluation of paclitaxel coatings for delivery via drug-coated balloons. *Eur J Pharm Biopharm* 2015;96:322–8.
17. Gibson CM, Mehran R, Bode C, et al. Prevention of bleeding in patients with atrial fibrillation undergoing PCI. *N Engl J Med* 2016;375:2423–34.
18. Dumont TM, Sonig A, Mokin M, et al. Submaximal angioplasty for symptomatic intracranial atherosclerosis: a prospective Phase I study. *J Neurosurg* 2016;125:964–71.
19. Lazzaro MA, Badruddin A, Abraham MG, et al. Proposed angiographic criteria for measurement of vertebral artery origin stenosis: the vertebral origin treatment with endovascular therapy (VOTE) method. *J Stroke Cerebrovasc Dis* 2012;21:712–6.
20. Ranke C, Rieder M, Creutzig A, et al. A nomogram of duplex ultrasound quantification of peripheral arterial stenoses. Studies of the cardiovascular model and in angiography patients. *Med Klin (Munich)* 1995;90:72–7.
21. Raghuram K, Seynnaeve C, Rai AT. Endovascular treatment of extracranial atherosclerotic disease involving the vertebral artery origins: a comparison of drug-eluting and bare-metal stents. *J Neurointerv Surg* 2012;4:206–10.
22. Jeng JS, Yip PK. Evaluation of vertebral artery hypoplasia and asymmetry by color-coded duplex ultrasonography. *Ultrasound Med Biol* 2004;30:605–9.
23. Hong JM, Chung CS, Bang OY, et al. Vertebral artery dominance contributes to basilar artery curvature and perivertebralbasilar junctional infarcts. *J Neurol Neurosurg Psychiatry* 2009;80:1087–92.
24. Stayman AN, Nogueira RG, Gupta R. A systematic review of stenting and angioplasty of symptomatic extracranial vertebral artery stenosis. *Stroke* 2011;42:2212–6.
25. Vajda Z, Miloslavski E, Guthe T, et al. Treatment of stenoses of vertebral artery origin using short drug-eluting coronary stents: improved follow-up results. *AJNR Am J Neuroradiol* 2009;30:1653–6.
26. Lin YH, Hung CS, Tseng WY, et al. Safety and feasibility of drug-eluting stent implantation at vertebral artery origin: the first case series in Asians. *J Formos Med Assoc* 2008;107:253–8.
27. Akins PT, Kerber CW, Pakbaz RS. Stenting of vertebral artery origin atherosclerosis in high-risk patients: bare or coated? A single-center consecutive case series. *J Invasive Cardiol* 2008;20:14–20.
28. Song L, Li J, Gu Y, et al. Drug-eluting vs. bare metal stents for symptomatic vertebral artery stenosis. *J Endovasc Ther* 2012;19:231–8.
29. Ko YG, Park S, Kim JY, et al. Percutaneous interventional treatment of extracranial vertebral artery stenosis with coronary stents. *Yonsei Med J* 2004;45:629–34.
30. Tesfamariam B. Local arterial wall drug delivery using balloon catheter system. *J Control Release* 2016;238:149–56.
31. Werner M, Braunlich S, Ulrich M, et al. Drug-eluting stents for the treatment of vertebral artery origin stenosis. *J Endovasc Ther* 2010;17:232–40.
32. Gruber P, Garcia-Esperon C, Berberat J, et al. Neuro Elutax SV drug-eluting balloon versus Wingspan stent system in symptomatic intracranial high-grade stenosis: a single-center experience. *J Neurointerv Surg* 2018;10:e32.
33. Gruber P, Braun C, Kahles T, et al. Percutaneous transluminal angioplasty using the novel drug-coated balloon catheter SeQuent Please NEO for the treatment of symptomatic intracranial severe stenosis: feasibility and safety study. *J Neurointerv Surg* 2019;11:719–22.
34. Pfisterer M, Brunner-La Rocca HP, Buser PT, et al. Late clinical events after clopidogrel discontinuation may limit the benefit of drug-eluting stents: an observational study of drug-eluting versus bare-metal stents. *J Am Coll Cardiol* 2006;48:2584–91.
35. Kleber FX, Rittger H, Bonaventura K, et al. Drug-coated balloons for treatment of coronary artery disease: updated recommendations from a consensus group. *Clin Res Cardiol* 2013;102:785–97.

## Are drug-coated balloons and drug-eluting stents the future in intracranial atherosclerotic disease?

1st February 2019 2401

Remonda L

Alternative treatment options for patients with intracranial atherosclerotic disease (ICAD) are needed, given its prevalence worldwide and the associated risk of recurrent ischaemic events. Here, Philipp Gruber and Professor Luca Remonda (Department of Neuroradiology at Cantonal Hospital Aarau, Aarau, Switzerland) look at previous studies to evaluate the viability of using drug-coated balloons (DCB) and drug-eluting stents (DES) in the treatment of intracranial atherosclerotic disease, and how they will play an increasingly important role in the not too distant future.

Intracranial atherosclerotic disease (ICAD) is responsible for 8–10% of strokes worldwide, its prevalence varies across populations, ranging from 10% in Caucasian up to about 40% in Asian populations. First-line therapy of symptomatic ICAD, in particular anti-platelet monotherapy, remains the best medical treatment. However, despite aggressive medical treatment, the annual risk of recurrent ischaemic events is still high with up to 18% in patients with >70% intracranial stenosis.<sup>1</sup> In particular, patients with high-grade stenosis (70–99%), patients with haemodynamically relevant stenosis—as shown in the natural history study GESICA<sub>2</sub>—and patients with unstable atherosclerotic plaque have an increased risk of stroke recurrence.

Therefore, alternative treatment modalities are needed.

Endovascular treatment (EVT) for symptomatic ICAD treatment has been long debated since the first description of percutaneous transluminal angioplasty in a symptomatic basilar ICAD by Sundt et al in 1980.<sup>3</sup> Since the negative SAMMPRIS and VISSIT trials,<sup>4</sup> endovascular treatment of symptomatic ICAD—especially percutaneous transluminal angioplasty stenting—has been reluctantly used. Nevertheless, recent results from the WAEVE trial demonstrated a significantly lower periprocedural stroke and death rate of 2.9%,<sup>5</sup> which encourages consideration of EVT for symptomatic intracranial atherosclerotic disease.



Besides immediate periprocedural complications such as local dissection, subarachnoid haemorrhage or perforator ischaemia, EVT of intracranial atherosclerotic disease also carries the middle- to long-term issue of restenosis. The restenosis rate for both PTA as well as transluminal angioplasty stenting has been reported to be high. Both transluminal angioplasty stenting and percutaneous transluminal angioplasty lead to vascular wall injuries that induce a complex biological cascade of inflammatory responses and wound healing processes. These processes promote the proliferation of smooth muscle cells leading to neo-intimal hyperplasia. It has been recognised that neo-intimal hyperplasia is mainly responsible for restenosis.

To overcome this major limitation of stenting and percutaneous transluminal angioplasty, various anti-proliferative and immuno-modulatory drugs have been evaluated to prevent neo-intimate hyperplasia. Today, two different drug families are most commonly used: the limus drug family, consisting of mammalian target of rapamycin (mTOR) inhibitors (e.g. sirolimus) and calcineurin inhibitors (e.g. Tacrolimus), which are used in drug-eluting stents, and paclitaxel, a highly lipophilic anti-proliferative agent that is a microtubule stabiliser that inhibits mitosis, which is commonly used in DCB's. Anti-proliferative drugs are integrated into a carrier matrix attached to either a balloon or stent platform. After deploying the DES or while inflating the DCB, the drug can be administered locally at the lesion site.

Both DCB and DES have been very successfully used in interventional cardiology for more than a decade. Numerous studies have proven their efficacy and safety for cardiac atherosclerotic patients. In the neurovascular field, several case series and a few studies have shown that this technique in patients with the primary symptomatic ICAD is feasible, safe and might be effective, while no data were available for DCB until 2018.

DCB offers several advantages over DES. Using DCB, no residual foreign body, nor radial force wall stress is left after the intervention. This has a positive impact on local flow dynamic as well as feared late adverse material-tissue reaction. Furthermore, DCB allows homogeneous anti-proliferative drug coverage of the whole stenosis surface in contrast to DES, by which only 15% of the plaque surface can be coated with anti-proliferative drugs. DCB are more flexible compared to DES offering access to reach more lesions, especially in the tortuous neurovascular anatomy of ICAD patients. A shorter duration of recommended dual anti-platelet therapy (DAPT) might be possible for DCB since there is a lower risk of delayed endothelialisation and therefore lower late or very-late thrombosis compared to DES as shown in cardiac patients. Of course there are drawbacks of percutaneous transluminal angioplasty alone in comparison to stenting, such as immediate recoil phenomenon or higher residual stenosis degrees that might have an impact

on restenosis.

Recently, two case series and one study have reported positive results on preliminary experience with DCB use in symptomatic ICAD. Our retrospective single-center cohort study of 19 symptomatic ICAD patients compared Neuro Elutax SV (Aachen Resonance, Germany)—a DCB specifically designed for neurovascular use—with the Gateway/ Wingspan stent system (Boston Scientific, USA).<sup>6,7</sup> We showed that the use of this specific DCB was feasible and safe. In addition, we found that this DCB treatment was superior to the DES regarding asymptomatic and symptomatic recurrence over a median follow-up of nine and a half months. Very recently, Chinese group reported on their preliminary DCB experience of 30 symptomatic ICAD patients using SeQuent Please (b.braun, Germany) with a mean follow-up of nearly ten months—a DCB originally designed for cardiac use.<sup>8</sup> Their results support our findings regarding feasibility and safety and there was only one asymptomatic restenosis. At the same time, another case series of 10 symptomatic ICAD patients treated at our institution with SeQuent Please NEO—the latest generation of SeQuent Please, offering higher flexibility and better pushability—demonstrated convincing results regarding feasibility and safety, as well as good short-outcomes.<sup>9</sup>

Presently, DCB offer several advantages over DES as outlined above. But, several issues have to be addressed. A clear concept for patient selection should be established, and it has to be discussed which deployment technique should be performed, such as the submaximal angioplasty technique as we have used in our studies. Despite all the technical advances during the past decade, the devices have to be optimised and closely adapted to the neurovascular requirements. Finally, large randomised trials should be carried out to increase the power and reliability of data.

In conclusion, alternative treatment options for ICAD patients are needed since ICAD has a high prevalence worldwide and even with the best medical treatment the risk of recurrent ischaemic events is high. DCB is a feasible and so far safe endovascular technique for ICAD patients. Therefore, the DCB technique has the potential to play an important role in symptomatic ICAD treatment in the near future.

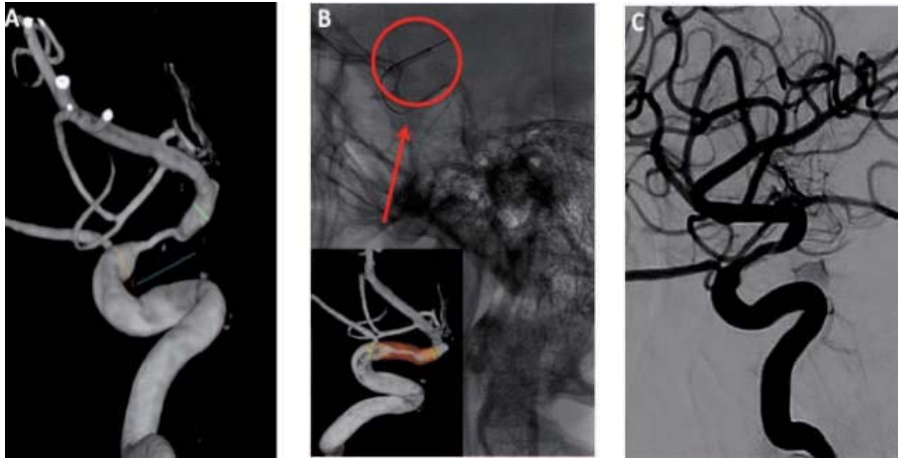


Figure 1: Illustrative Case of DCB use in a symptomatic ICAD patient

A patient with an ischaemic event in the posterior middle cerebral artery territory due to a symptomatic high-grade stenosis of the terminal internal carotid artery segment carotid artery stenosis on the same side.

1 Pre-interventional reformatted 3D-conventional angiogram showed a eccentric high-grade terminal internal carotid artery stenosis (80%).

2 SeQuent Please NEO (2.0mm x10mm) was successfully deployed over the lesion (red circle) and submaximally inflated with 8 bar.

3 Post-interventional control angiogram revealed a residual stenosis (50%).

Philipp Gruber and Professor Luca Remonda are affiliated with the Department of Neuroradiology at Cantonal Hospital Aarau, Aarau, Switzerland.

## References

- 1 Kasner S.E., Chimowitz M.I., Lynn M.J., et al: Warfarin Aspirin Symptomatic Intracranial Disease Trial Investigators. Predictors of ischemic stroke in the territory of a symptomatic intracranial arterial stenosis. *Circulation* 2006; 113: pp. 555-563.
  - 2 Mazighi M, Tanasescu R, Ducrocq X, Vicaut E, Bracard S, Houdart E, Woimant F: Prospective study of symptomatic atherothrombotic intracranial stenoses: the GESICA study. *Neurology* 2006, 66(8):1187-1191.
  - 3 Sundt TM, Jr., Smith HC, Campbell JK, Vlietstra RE, Cucchiara RF, Stanson AW: Transluminal angioplasty for basilar artery stenosis. *Mayo Clin Proc* 1980, 55(11):673-680.
  - 4 Zaidat OO, Fitzsimmons BF, Woodward BK, Wang Z, Killer-Oberpfalzer M, Wakhloo A, Gupta R, Kirshner H, Megerian JT, Lesko J et al: Effect of a balloon-expandable intracranial stent vs medical therapy on risk of stroke in patients with symptomatic intracranial stenosis: the VISSIT randomized clinical trial. *JAMA* 2015, 313(12):1240-1248.
  - 5 WAEVE trial, presentation at International Stroke Conference 2018
  - 6 Gruber P, Garcia-Esperon C, Berberat J, Kahles T, Hlavica M, Anon J, Diepers M, Nedeltchev K, Remonda L: Neuro Elutax SV drug-eluting balloon versus Wingspan stent system in symptomatic intracranial high-grade stenosis: a single-center experience. *J Neurointerv Surg* 2018, 10(12):e32.
  - 7 Chimowitz MI, Lynn MJ, Derdeyn CP, Turan TN, Fiorella D, Lane BF, Janis LS, Lutsep HL, Barnwell SL, Waters MF et al: Stenting versus aggressive medical therapy for intracranial arterial stenosis. *N Engl J Med* 2011, 365(11):993-1003.
  - 8 Han J, Zhang J, Zhang X, Zhang J, Song Y, Zhao W, Zheng M, Sun L, Wang W: Drug-coated balloons for the treatment of symptomatic intracranial atherosclerosis: initial experience and follow-up outcome. *J Neurointerv Surg* 2018.
- Gruber P, Braun C, Kahles T, Hlavica M, Anon J, Diepers M, Nedeltchev K, Berberat J, Remonda L: Percutaneous transluminal angioplasty using the novel drug-coated balloon catheter SeQuent Please NEO for the treatment of symptomatic intracranial severe stenosis: feasibility and safety study. *J Neurointerv Surg* 2018.

## LITERATURE REVIEW

**NEURO ELUTAX SV DRUG-ELUTING BALLOON VERSUS WINGSPAN STENT SYSTEM IN SYMPTOMATIC INTRACRANIAL HIGH-GRADE STENOSIS  
A SINGLE-CENTER EXPERIENCE****Phuyal S\***

\*Subash Phuyal, Consultant interventional neuroradiologist, Grande International Hospital, Kathmandu

Correspondence: drsphuyal17@gmail.com

Intracranial stenosis is a major cause of stroke worldwide, prevalent more in Asian populations. The treatment of ICAD (intracranial atherosclerotic disease) remains relatively conservative, owing to the trends following SAMMPRIS trial. SAMMPRIS trial established superiority of conservative management over intracranial stenting. However in SAMPRISS trial, significant re strokes were noted on medical management. Therefore, aggressive medical management does not offer the ideal solution and a novel treatment strategy for ICAD is desired.

Since 1980s, simple angioplasty for ICAD has been tried. Mainly cardiac balloons have been used for intracranial angioplasty however, owing to stiff nature of cardiac hardware these devices are difficult to navigate intracranially. Similar difficulties are encountered in intracranial stenting. This has resulted in higher percentage of procedural and periprocedural complications leading to relatively poor outcome.

Recently a CE certified intracranial drug eluting balloon was compared to Wingspan stents in a study 'Neuro Elutax SV drug-eluting balloon versus Wingspan stent system in symptomatic intracranial high-grade stenosis: a single-center experience.' It was a single-center, open-label, retrospective cohort study of 19 patients with symptomatic atherosclerotic intracranial high-grade stenosis treated with either Elutax DEB (drug eluting balloon) or Wingspan Stent from a tertiary stroke center in Switzerland.

Results: Eight patients received Elutax DEB. Median clinical follow-up was 10 months for the Wingspan Stent and 9.5 months for Elutax DEB ( $P=0.36$ ). No differences were found in the clinical baseline characteristics, with a median stenosis grade of 80% for the Wingspan stent and 81% for the Elutax DEB ( $P=0.87$ ). The compound endpoint 'ischemic re-event and/or restenosis' was significantly lower for Elutax DEB (13% vs 64%;  $P=0.03$ , OR 0.08 (95% CI 0.007 to 0.93;  $P=0.043$ ) than for the Wingspan stent.

Compared to previous cardiac hardware Elutax DEB is easy to navigate intracranially and allows delivery of paclitaxel within 30 seconds, which inhibits the ICAD/plaque regrowth. DEB angioplasty is indicated in symptomatic ICAD and stenosis of 70% or more. This study suggests that Elutax DEB angioplasty for ICAD is safe and with less complications as compared to intracranial stenting. This promising treatment option should undergo bigger trials and evaluations.

Available at: <https://jniss.bmj.com/content/10/12/e32.long>